

DANYLO HALYTSKYLVIV NATIONAL MEDICAL UNIVERSITY

Department of Pediatric Dentistry

Methodological Recommendations

Pediatric Dental Surgery

**for preparing of specialists of the second (master) level
of higher education
*4th year, 8th semester***

(for students)

Lviv 2021

Composed by:

Grynyshyn O.B., assist., PhD; Skybchyk O.V., assist.; Fur M.B., assoc. Prof., PhD

Chief Editor: Kolesnichenko O.V., Assoc. Prof., PhD

Reviewed by: Chukhray N.L., Prof., Doctor of medical science

Ripetska O.R., Assoc. Prof., PhD

Manyuk L.V., senior lecturer

Considered and approved on meeting of Pediatric Dentistry Department (protocol № 7, from 09.04.2021) and Profiled Methodical Commission of Dental faculty (protocol № 2, from 29.04.2021)

Methodical recommendations were discussed, re-approved and confirmed at the meeting of the Department of Pediatric Dentistry of Lviv National Medical University named after Danylo Halysky

Protocol № from « » _____ 202

Protocol № from « » _____ 202

Protocol № from « » _____ 202

Protocol № from « » _____ 202

Protocol № from « » _____ 202

**Responsible for the issue
Vice-Rector for Academic Affairs, Professor M.R. Grzegotskyy**

The structure of the discipline

(3 credits, 90 hours: 10 hours of lectures, 40 hours of practical lessons / 40 hours of self-work)

Theme	Hours		
	whole	Including	
		Practical lessons	Self-work
Theme №1. Anatomical and physiological features of the development and structure of tissues and organs of the maxillofacial area in children. Anesthesia for maxillofacial area surgery in children in ambulatory and hospital. Operation of extraction of primary and permanent teeth.	8	4	4
Theme №2. Odontogenic and non-odontogenic, acute and chronic periostitis of the jaws. Clinic, diagnostics, differential diagnostics. Surgical treatment. Complications, their treatment and prevention.	8	4	4
Theme № 3. Acute odontogenic osteomyelitis of the jaws in children. Acute non-odontogenic osteomyelitis of the jaws in children. Chronic osteomyelitis of the jaws in children.	8	4	4
Theme № 4. Odontogenic, non-odontogenic abscesses and phlegmones of the maxillofacial area. Classification, clinic and diagnosis depending on the localization of the inflammatory focus. Differential diagnostics. Surgical treatment and its complications. General principles of complex treatment.	8	4	4
Theme № 5. Odontogenic inflammatory jaw cysts of primary and permanent teeth. Clinic, diagnostics, differential diagnostics. Methods of treatment.	8	4	4
Theme № 6. Acute and chronic, odontogenic and non-odontogenic lymphadenitis of the maxillofacial area. Complications and its prevention.	8	4	4
Theme № 7. Acute diseases of the salivary glands in children: epidemic parotitis, non-epidemic parotitis, calculous and non-calculous submaxillitis. Chronic diseases of the salivary glands in children: parenchymal and interstitial submaxillitis. Clinic, diagnosis, treatment and prevention of diseases of the salivary glands in children.	8	4	4
Theme № 8. Acute and chronic inflammatory diseases of temporomandibular joint (TMJ) in children. Secondary osteoarthritis, ankylosis. Causes of development, diagnosis, differential diagnosis, clinical course. Principles and stages of surgical and medicamentous treatment. Rehabilitation of such patients.	8	4	4
Theme №9. Traumatic injuries of the soft tissues. Burns and frostbites.	8	4	4

Theme №10. Furuncles and carbuncle of the maxillofacial area. Classification, diagnosis, differential diagnosis, treatment. Complications and its prevention. Summary lesson. Differentiated test.	8	4	4
Whole	80	40	40

Theme of lectures

№	Theme	Hours
1	Anatomical and physiological features of development and structure of tissues and organs of the maxillofacial area in children. Local and general anesthesia in children. Indications and contraindication for tooth extraction in children, technique of its conduction, tools. Peculiarities of extraction of primary and permanent teeth in children, prevention of its complications.	2
2	Inflammatory processes of the maxillo-facial area in children. Acute and chronic periostitis. Acute and chronic osteomyelitis. Inflammatory cysts of the jaws from primary and permanent teeth.	2
3	Inflammatory processes of the soft tissues of the maxillo-facial area in children (abscesses, phlegmons, lymphadenitis). Specific inflammatory diseases.	2
4	Anatomical and physiological features of the salivary glands and TMJ in children at different age. Inflammatory acute and chronic diseases of the salivary glands and TMJ in children.	2
5	Causes of child injuries and its prevention. Diagnosis, clinical manifestation of injuries of the soft tissues of the maxillofacial area in children. Principles of the plastic surgery which are used for surgical processing of wounds. Treatment and consequences of the traumatic injuries of the soft tissues of face in children.	2
	Whole	10

Self-work

№	Theme	Hours	Type of control
1.	Paint schemes - pictures innervation and vascularization teeth of the upper and lower jaw.	4	Current
2.	Anatomical and physiological peculiarities of primary and permanent teeth, jaws in children.	4	Current
3.	Prescription drugs that are used in the treatment of odontogenic jaw abscess in children indicate their pharmacological effects.	4	Current
4.	Draw a scheme of rational sections in the area of head and neck in the presence of inflammation in the soft tissues.	4	Current
5.	Draw a diagram of operations cystotomy and cystectomy	4	Current
6.	Prescription medicines used in the treatment of lymphadenitis in children	4	Current
7.	Draw a diagram of the topographic location of the major salivary glands, the location of their excretory ducts	4	Current

8.	To chart dif. diagnose diseases TMJ with other diseases	4	Current
9.	Anatomical and physiological peculiarities of structure of the soft tissue of the maxillofacial ares in children, which can cause peculiarities of the traumatic injuries.	4	Current
10.	To chart the necessary resuscitation in emergency conditions (anaphylactic shock, collapse, dizziness).	4	Current
	Whole	40	

The minimum converted number of points of current achievement for the discipline "Pediatric Dental Surgery" is **72 points**.

The maximum converted number of points of current achievement for the discipline "Pediatric Dental Surgery" is **120 points**.

The maximum number of points for Differentiated test is 80 points.

The minimum number of points for the **for Differentiated test** under which control is considered to be passed is **50 points**.

The maximum number of points per course is 200 points.

The methodology of practical training in the discipline "Pediatric Dental Surgery" (4 years 8 semesters) provides:

1. Control of the student's self-work in preparation for the lesson of the current practical theme by checking the student's written performance in the *Workbook* of the relevant tasks - **20 minutes**.

2. Test control (*level $\alpha - 2$*) of the initial level of knowledge and determination of the degree of students' readiness for the class – **30 minutes**.

3. Individual *oral questioning* of students, clarification of individual questions of the topic of the current class, answers to students' questions - **40 minutes**.

4. During the **50 minutes**, the students independently during the undergo certain dental manipulations on the phantoms/

5. Control of the *final level* of students' knowledge - **40 minutes**. It is carried out in the form of solving test problems (*level $\alpha - 3$*), individual oral questioning, solving situational problems.

At the end of the practical lesson, the teacher summarizes its results, gives students the tasks for independent work, points to the nodal questions of the next topic and offers a list of recommended literature for independent study.

Theme. Anatomical and physiological features of the development and structure of tissues and organs of the maxillofacial area in children. Anesthesia for maxillofacial area surgery in children in ambulatory and hospital. Operation of extraction of primary and permanent teeth.

Aim of the lesson. To study the structure and features of the maxillofacial area in children in the age aspect. To repeat embryogenesis and anatomy of the maxillofacial area. Discuss the importance of knowledge of the structure and features of MFA in children. The methods of primary and permanent teeth extraction in part-time department, indications and contraindications to the teeth extraction.

Control of the initial level of knowledge

1. Periods of development of organs of MFA in children.
2. Embryogenesis of the mouth, jaws and teeth.
3. Features of the structure of oral cavity in children.

Content of the lesson

Knowledge of the anatomical and physiological characteristics of the maxillofacial area is required for understanding of pathological processes (trauma, infection, tumor processes), development and manifestation of which is directly connected to the structure and condition of the organs and tissues.

The oral cavity is oval shaped and is separated into the oral vestibule and the oral cavity proper. It is bound by the lips anteriorly, the cheeks laterally, the floor of the mouth inferiorly, the oropharynx posteriorly, and the palate superiorly. The oropharynx begins superiorly at the junction between the hard palate and the soft palate, and inferiorly behind the circumvallate papillae of the tongue. The bony base of the oral cavity is represented by the maxillary and mandibular bones.

The oral cavity includes the lips, gingivae, retromolar trigone, teeth, hard palate, cheek mucosa, mobile tongue, and floor of the mouth. The major salivary glands are in close relation with oral cavity structures, although they are not part of the oral cavity. The palatine tonsils, soft palate, tongue base, and posterior pharyngeal walls are part of the oropharynx; the oropharynx is not part of the oral cavity.

The oral vestibule is bounded externally by the lips and the cheek mucosa and internally by the alveolar processes and the teeth. When the teeth are in occlusion, the vestibule communicates with the oral cavity proper via the intermaxillary commissure behind the last molar teeth.

Lips. The longer upper lip and shorter lower lip are connected to each other by the labial commissures at the corners of the mouth. The lips are separated from the cheeks by the nasolabial fold. The lip has an interior pale wet vermilion and an outer darker dry vermilion, separated from each other by the red line; there is also a white line on the outside that is the purely cutaneous part of the lip.

Cheeks (mucosa). The cheeks are a musculomembranous structure and are limited superiorly and inferiorly by the upper and lower vestibules, anteriorly by the labial commissure, and posteriorly by the retromolar trigone and the intermaxillary commissure. The inner surface of each lip is connected in the middle line to the corresponding gum by a fold of mucous membrane, the labial frenulum. The upper labial frenulum is larger than the lower labial frenulum.

The retrocommissural region is situated between the labial commissure and the opening of Stensen's duct (the drainage duct of the parotid gland), located opposite the second upper molar. Stensen's duct runs through the buccinator muscle. A horizontal slightly elevated streak (called the linea alba or occlusal line) traverses this region.

The buccinator muscle forms the muscular framework of the cheek and is also a muscle of facial expression. It is covered by the buccal fat pad, which smoothes the cheek contour by filling in the depression and the anterior border of the masseter. The masseter muscle covers the buccinator. Other muscles also contribute to the formation of the cheek, such as the zygomaticus, risorius, and platysma.

Gums and alveolar process. The gingiva (or gum) is a fibroepithelial mucosal tissue that surrounds the teeth and covers the alveolar jawbone.

The alveolar process is the tooth-bearing area of the jaws. It is composed of a dense outer cortex (known as the cortical plate) and looser inner trabecular (or medullary) bone. The area of cortical bone that lines the dental socket (or alveolus) is called the lamina dura.

Retromolar trigone. The retromolar trigone is a small triangular-shaped subsite of the oral cavity. It is the portion of mucosa that lies behind the third molar tooth, covering the anterior ramus of the mandible. The base of the triangle is posterior to the last inferior molar tooth; the apex is in continuity with the tuberosity of the maxilla behind the last upper molar tooth. The retromolar trigone is bounded laterally by the gingival buccal sulcus and medially by the anterior tonsillar pillar.

Teeth. The teeth are calcified structures whose main purpose is mastication. Each tooth is composed of a crown, which is the exposed portion above the gumline, and a root, which is embedded in the jawbone.

Deciduous teeth (also referred to as primary or temporary teeth) are the first to emerge in the oral cavity and are progressively replaced by the permanent (or adult) dentition. There are 20 deciduous teeth, comprising 8 molars, 4 canines (or cuspids), and 8 incisors. The permanent dentition consists of 32 teeth: 12 molars (including 4 so-called wisdom teeth or third molars), 8 premolars (or bicuspids), 4 canines, and 8 incisors.

Incisors have a thin occlusal edge, a somewhat flat crown, and a single root. Their main purpose is to cut food. Canines have a pointed shape and single long roots. Their main function is to pierce and tear food.

The occlusal (or masticatory) surface of molars and premolars is characterized by pointed structures named cusps. Premolars usually have 1 or 2 cusps and 1 or 2 roots. Molars usually have 4-5 cusps and 2-3 roots, the shape of which is highly variable. The purpose of molars and premolars is to grind and crush food.

Hard palate. The palate is the horseshoe-shaped, domed roof of the oral cavity. It is divided into a hard portion and a soft portion. The hard palate belongs to the oral cavity and separates it from the nasal cavities. The soft palate belongs to the oropharynx and separates it from the nasopharynx.

The hard palate is concave, and this concavity is occupied mostly by the tongue when it is at rest. The hard palate is subdivided into the primary and secondary palates. The primary palate is separated from the secondary palate by a small depression behind the central incisors termed the incisive fossa, where the incisive foramen opens.

The anterior two thirds of the hard palate is formed by the incisive bone, or premaxilla, and the palatine processes of the maxilla. The horizontal plates of the palatine bone form the posterior third. The secondary palate presents a midline elevated suture line termed the median or palatine raphe. The hard palate also has transverse ridges (or rugae) on the anterior third that serve to retain the food bolus.

Soft palate. The soft palate marks the beginning of the oropharynx and is the movable posterior third of the palate. It forms an incomplete septum between the mouth and the pharynx. It is marked by a median raphe and is continuous with the roof of the mouth and the mucous membrane of the nasal floor.

When the soft palate is relaxed, its anterior surface is concave and its posterior surface is convex. The anterior aponeurotic portion is attached to the posterior border of the hard palate, and the posterior muscular portion hangs between the mouth and the pharynx and is termed the palatine velum (or velopharynx).

The velum is prolonged by a median free process termed the uvula and 2 bilateral processes termed the palatoglossal and palatopharyngeal arches or pillars, which join the soft palate to the tongue and pharynx, respectively. The fauces represent the space between the cavity of the mouth and the oropharynx. They are bounded superiorly by the soft palate, inferiorly by the root of the tongue, and laterally by the pillars of the fauces.

The palatine tonsils are located in the tonsillar sinuses (or fossae) of the oropharynx, which is bounded by the palatoglossal and palatopharyngeal arches and the tongue.

During swallowing, the soft palate is initially tensed to squeeze the bolus of food between the tongue and pharynx before elevation of the soft palate to block the nasal passages while the bolus is propelled into the pharynx.

Floor of mouth. The floor of mouth forms the inferior limit of the oral cavity. It is often compared to a quadrangular pyramid with a posterior base. Superficially, it is separated into 3 zones: the anterior floor of the mouth located anterior to the lingual frenulum and the 2 sublingual folds located between the lateral tongue and the mandibular gingiva.

The sublingual papillae (also referred to as caruncles or folds) can be identified on both sides of the frenulum in the anterior part of the floor of mouth when the tip of the tongue is raised. The excretory duct of the submandibular gland (Wharton's duct) runs in the floor of the mouth along the medial border of the sublingual gland to pierce the surface of the mouth at the paramedian sublingual caruncle. The sublingual glands have multiple small ducts that drain directly into the floor of the mouth.

Tongue and major salivary glands. The tongue is a mobile muscular organ that occupies the major part of the oral cavity and part of the oropharynx. Its main functions are pushing food into the oropharynx during swallowing and forming words during speaking, although it is also implicated in mastication, taste, and oral cleansing. The macroscopic and microscopic anatomy, musculature, nerve supply, and vasculature of the tongue are specifically addressed elsewhere.

The major salivary glands are large paired exocrine glands that communicate with the mouth and pour their secretions into its cavity. They comprise the parotid, submandibular (or submaxillary), and sublingual glands.

Because food is physically broken down in the oral cavity, this region is lined by a protective, nonkeratinized, stratified squamous epithelium, which also lines the inner surface of the lips. The oral cavity proper is lined by a masticatory mucosa (gingiva and hard palate), a lining mucosa (lips, cheeks, alveolar mucosal surface, floor of the mouth, inferior surface of the tongue, soft palate), and a specialized mucosa (dorsal surface of the tongue). The histologic structure of the tongue is addressed elsewhere.

Minor salivary glands. The basic structure of a salivary gland is that of a branching duct that has the principal secretory cells (the acinar cells) at the proximal ends of the branches and an opening into the oral cavity at the other end of a single collecting duct. Four morphologically and functionally varying segments exist in each basic salivary gland unit: acinus, intercalated duct, striated duct, and excretory duct. Two types of cells exist in each segment: abluminal cells and luminal cells.

The abluminal cells are myoepithelial cells in the acinus and intercalated duct and basal cells in the striated and excretory ducts. Acinar cells may be serous or mucous, depending on the chemical composition of the saliva produced by a specific gland. Parotid glands are mostly serous, submandibular glands are mixed (predominantly serous), sublingual glands are mixed (predominantly mucous), and minor salivary glands are mixed (predominantly mucous), except in the palate, where the glands are mostly mucous, and in the tongue.

The oral cavity is scattered with 500-1000 minor salivary glands within the mucosa and submucosa of the cheeks, lips, floor of the mouth, hard and soft palates, retromolar trigone, and tongue; the anterior hard palate and gingivae are devoid of these glands.

The lobules of the minor salivary glands are 1-5 mm in size and are separated from one another by connective tissue. Glands in the posterior hard palate are more numerous and more confluent. Most lobules have individual excretory ducts that open into the oral cavity, but they are not usually perceptible.

In the tongue, lips, and buccal mucosa, lobules of salivary gland tissue are located beneath the mucosal epithelium and within the deeper skeletal muscles. These glands are unencapsulated.

The posterior hard palate contains pure mucous type acini without serous cells. In the tongue, Blandin and Nunn glands are located on the anterior ventral portion and are of the mucous type. The posterior dorsal and lateral portions contain serous glands called von Ebner glands.

The movements of the mandible are mainly produced by the **4 muscles of mastication**: the masseter, temporalis, lateral pterygoid, and medial pterygoid muscles. All of these muscles come from the mesoderm of the first pharyngeal arch, and their innervation is therefore supplied by the anterior trunk of the mandibular nerve (cranial nerve V3).

The masseter is a quadrangular muscle that has a deep part and a superficial part. The deep portion originates from the inferior surface of the zygomatic arch and descends almost vertically to insert onto the lateral surface of the ramus. The superficial portion arises from the zygomatic bone anterior to the temporozygomatic suture and descends inferiorly and posteriorly to insert onto the angle of the mandible. The main action of the masseter is mandibular elevation. Some superficial fibers also have a limited role in mandibular protrusion.

The temporalis is a broad triangular muscle that originates from the floor of the temporal fossa and from the deep surface of the temporal fascia. It inserts on the tip and medial surface of the coronoid process and on the anterior border of the ramus of the mandible. Its main action is to elevate the mandible. Some horizontal fibers are also involved in mandibular retraction.

The lateral pterygoid muscle is a 2-headed triangular muscle that has 2 distinct origins: the infratemporal surface and crest of the greater wing of the sphenoid and the lateral surface of the lateral pterygoid plate. The upper head inserts onto the joint capsule and articular disc of the temporomandibular joint. The inferior head attaches to the anteromedial aspect of the neck of the condyle. Bilateral contraction of this muscle causes protraction of the mandible and depression of the chin. Unilateral contraction moves the jaw contralaterally.

The medial pterygoid muscle is also a 2-headed muscle; it originates from the medial surface of the lateral pterygoid plate and the pyramidal process of the palatine bone and from the maxillary tuberosity. It inserts onto the medial surface of the ramus of the mandible. Its main role is mandibular elevation, in synergy with the masseter muscle. It also contributes to mandibular protrusion.

Mandibular depression is mainly produced by gravity. The suprahyoid and infrahyoid muscles, whose chief roles are to raise and depress the hyoid bone and the larynx, respectively, may also participate in mandibular depression.

Blood Supply and Lymphatic Drainage

Blood is supplied to the oral vestibule and oral cavity via branches of the external carotid artery (facial, maxillary, and lingual). The terminal branches of the arteries often anastomose freely, including anastomoses across the midline with their contralateral partners.

The facial artery provides the major arterial supply to the lips. It branches out into the superior and inferior labial arteries 1 cm lateral to the corner of the mouth. The superior labial artery supplies the upper lip. The inferior nasal artery supplies the lower lip. These arteries anastomose with each other to form an arterial ring.

The angular artery, a terminal branch of the facial artery, supplies the superior part of the cheek. The facial vein provides venous drainage to the lips. It joins with a communication of the retromandibular vein to form the common facial vein and terminates in the internal jugular vein at the level of the hyoid bone.

The maxillary artery is the larger of the 2 terminal branches of the external carotid and supplies the cheek mucosa, teeth, gingivae, and palate. It arises behind the mandibular neck and is at first embedded in the substance of the parotid gland. As it emerges, it is divided into 3 portions: mandibular, pterygoid, and pterygopalatine.

The mandibular portion of the maxillary artery gives off the inferior alveolar artery, which enters the mandible and supplies the mandibular teeth, chin, and mylohyoid muscle.

The pterygoid portion branches out into the masseteric artery, which supplies the masseter; the deep temporal arteries, which supply the temporalis muscle; the pterygoid branches, which supply the pterygoid muscles; and the buccal artery, which supplies the buccal fat pad, buccinator, and buccal oral mucosa.

The pterygopalatine portion of the maxillary artery branches into the posterior superior alveolar artery, the infraorbital artery, the artery of the pterygoid canal, the pharyngeal branch, the descending palatine artery, and the sphenopalatine artery.

The posterior superior alveolar artery supplies the maxillary molar and premolars and the adjacent gingiva. The infraorbital artery supplies the maxillary canines and incisors and the skin of the infraorbital region of the face. The descending palatine artery descends through the palatine canal and divides into the greater and lesser palatine arteries to supply the mucosa and glands of the hard and soft

palate. The sphenopalatine artery traverses the sphenopalatine foramen to supply the anteriormost palate.

The deep facial vein, which originates from the pterygoid venous plexus, drains most of the areas supplied by the maxillary artery. It enters the posterior aspect of the facial vein, which terminates in the internal jugular vein.

The lingual artery, its branches, and the lingual veins provide circulation to the tongue and the floor of the mouth. All of the lingual veins terminate, directly or indirectly, in the internal jugular vein after merging into the common trunk for lingual and facial veins.

All lymphatics from the head and neck drain directly or indirectly into the deep cervical lymph nodes. Lymph from these nodes then drains into the jugular lymphatic trunk, which joins the thoracic duct on the left side and the internal jugular vein or brachiocephalic vein on the right side.

The skin of the cheeks drains to parotid and submandibular lymph nodes. The upper lip and the lateral parts of the lower lip drain to the submandibular lymph nodes. Lymph from the central part of the lower lip drains to the submental lymph nodes. Lymph from the mucous membrane of the cheek drains to submandibular nodes and to upper deep cervical nodes. Superficial cervical nodes may also be involved.

Both surfaces of the lower gingivae and the outer surface of the upper gingivae drain into submandibular lymph nodes. The inner surface of the upper gums is drained with the vessels of the hard and soft palates to the upper deep cervical lymph nodes. The floor of the mouth drains via lymphatics that pierce the mylohyoid muscle to reach the submental nodes anteriorly or the submandibular nodes posteriorly.

Innervation. Sensory innervation to the lips, cheeks, gingivae, teeth, hard palate, and floor of the mouth is provided by the trigeminal nerve (cranial nerve V), more specifically the maxillary (V2) and mandibular (V3) divisions of this nerve. Branches of V3 also supply the 4 muscles of mastication, but the motor innervation of the buccinator and orbicularis oris muscles is supplied by the buccal branch of the facial nerve (VII).

In the upper jaw, the buccal and gingival mucosa are supplied by both the maxillary and mandibular divisions; in the lower jaw, they are supplied only by the mandibular division.

The maxillary nerve (V2) leaves the cranium through the foramen rotundum in the sphenoid and enters the pterygopalatine fossa, where it gives off branches to the pterygopalatine ganglion and enters the inferior orbital fissure. It gives off the zygomatic nerve and passes into the infraorbital groove as the infraorbital nerve.

The posterior and middle superior alveolar nerves arise from the maxillary nerve, and the anterior superior alveolar nerve arises from the infraorbital nerve. These nerves supply the maxillary molars. The gingival branch arises from the posterior superior alveolar nerve and supplies the mucosa of the gingiva and of the cheek near the upper molars.

The infraorbital branch of the maxillary nerve gives off palatine branches. This nerve also supplies the mucosa of the upper lip and labial vestibule.

The mandibular nerve (V3) descends through the foramen ovale into the infratemporal fossa and divides into the auriculotemporal, inferior alveolar, lingual, and buccal nerves.

The inferior alveolar nerve enters the mandibular foramen, passes through the mandibular canal, and forms the inferior dental plexus. The inferior dental plexus sends branches to all mandibular teeth on its side. The mental nerve is another branch of the plexus that supplies the skin and mucous membrane of the lower lip and the vestibular gingiva of the mandibular incisors. The lingual nerve lies anterior to the inferior alveolar nerve and provides sensory innervation to the floor of the mouth and the lingual gingiva.

Surgical extraction is the method by which a tooth is removed from its socket. The technique of teeth extraction is relatively simple procedure within a general practitioner's scope if the basic principles of the surgical technique are followed.

Indications for the primary teeth extraction:

- The tooth is responsible of the acute septic state;
- The tooth is the source of the acute odontogenic processes (permanent exacerbated

periostitis, osteomyelitis);

- the host's defense system is weakened;
- arresting of the root formation before ending of the root development;
- damaging of the cortical lamina of the permanent tooth follicle by inflammatory process;
- pathological or physiological root resorption more than for 1/3 of its length;
- tooth mobility (II-III degree);
- the crown of the tooth is destroyed and the physiological tooth changing occurs in 18

months;

- root or tooth floor perforation;
- inner resorption of the roots;
- extensive pathological destroying of the bone;
- the failure of the conservative treatment;
- the patients with complicated anamnesis vitae;
- retained primary tooth with radiographic evidence of the presence of permanent tooth.

Indications for the extraction of the permanent teeth:

- Teeth which are responsible for the acute odontogenic osteomyelitis of the jaws (mainly molars);
- Teeth with chronic periodontitis which can not be cured with conservative or surgical methods of treatment (dental hemisection, replantation, apicectomy, root amputation);
- severe decay of coronal part of the tooth, when it is impossible to make use of tooth root for prostodontic purpose;
- supplemental and impacted tooth without possibility of their eruption;
- deciduous teeth without changing till 15 years with roentgenological confirmation of the permanent tooth presence in second dentition;
- intact teeth which are located into the line of jaw fracture and prevent bone fragment from reposition;
- teeth with periapical inflammation which are located into the line of jaw fracture and do not prevent bone fragment from reposition;
- longitudinal or splintered root fracture;
- orthodontic purpose

Conditional contraindication for the teeth extraction:

- cardio-vascular disorders (stenocardia, arrhythmia, rheumatism, endocarditis and myocarditis in the stage of exacerbation, cardiac decompensation);
- renal diseases (acute glomerulonephritis, renal insufficiency);
- acute infectious disease;
- CNS disorders;
- mental disorders in the exacerbation period;
- acute inflammatory disorders of the oral mucosa;
- teeth which are located in the focus of malignant tumor or bone hemangioma;
- acute disorders of air passageways.

Pre- and postoperative complications.

Postoperative pain. Discomfort after the surgical trauma of dental extractions is to be expected and may be alleviated with an analgesic such as paracetamol or a non-steroidal anti-inflammatory drug (NSAID) such as ibuprofen. Severe pain after a dental extraction is unusual and may indicate that another complication has occurred.

Postoperative swelling. Mild inflammatory swelling may follow dental extractions but is unusual unless the procedure was difficult and significant surgical trauma occurred. More significant swelling usually indicates postoperative infection or presence of a haematoma. Management of infection may require systemic antibiotics or drainage. A large haematoma may need to be drained. Less likely is surgical emphysema (see below).

Trismus. Trismus or limited mouth opening after a dental extraction is unusual and is likely to be infective in origin.

Fracture of teeth. Teeth may fracture during forceps extraction for a variety of reasons and this is not an unusual event. The crown may fracture because of the presence of a large restoration, but this may not prevent the extraction from continuing as the forceps are applied to the root. However, if the fracture occurs subgingivally, then a transalveolar approach will be necessary to visualize the root. If a small (3 mm) root apex is retained after extraction, this may be left in situ, providing it is not associated with apical infection. The patient must be informed of the decision to leave the apex to avoid the morbidity associated with its surgical retrieval and the decision recorded. Antibiotics should be prescribed.

Excessive bleeding. It may be difficult to gauge the seriousness of the blood loss from the patient's history, because they are usually anxious. However, it is important to establish whether or not the patient is shocked by measuring the blood pressure and pulse. This can be done while the patient bites firmly on a gauze swab to encourage haemostasis. Typically, if the systolic pressure is below 100 mmHg and the heart rate in excess of 100 beats/min, then the patient is shocked and there is an urgent need to replace lost volume. This may be done by infusion of a plasma expander such as Gelofusine or Haemaccel or a crystalloid such as sodium chloride via a large peripheral vein. For this purpose, the patient should be transferred to a hospital. More commonly, the patient is not shocked and can be managed in the primary care setting.

The next step in management is to investigate the cause of the haemorrhage by taking a history and carrying out an examination.

History

- Local causes
 - mouthrinsing
 - exercise
- General causes
 - previous postextraction or surgical haemorrhage
 - medications
 - liver disease
 - family history of disorders of haemostasis.

Examination

Determine the source of the haemorrhage by sitting the patient upright (unless feeling faint) and using suction and a good light. This is commonly from capillaries of the bony socket or the gingival margin of the socket, or more unusually from a large blood vessel or soft tissue tear. Achieve haemostasis. If the history has suggested a general cause, then local methods will not adequately result in haemostasis and the patient should be transferred to a hospital where the specialist's haematological management is available.

Otherwise the following techniques are used:

- socket capillaries: pack the socket with resorbable cellulose, such as Surgicell
- gingival capillaries: suture the socket with a material that will permit adequate tension, such as vicryl or black silk
- large blood vessel: ligate vessel, usually by passing a suture about the vessel and soft tissues.

Dry socket (alveolar osteitis). In some cases, a blood clot may inadequately form or be broken down. Predisposing factors of osteitis include smoking, surgical trauma, the vasoconstrictor added to a local anaesthetic solution, oral contraceptives and a history of radiotherapy. The exposed bone is extremely painful and sensitive to touch.

Dry socket is managed by:

- reassuring the patient that the correct tooth has been extracted
- irrigation of socket with warm saline or chlorhexidine mouthrinse to remove any debris
- dressing the socket to protect it from painful stimuli: bismuth-iodoform-paraffin paste (BIPP) and lidocaine (lignocaine) gel on ribbon gauze are useful.

Postoperative infection. In some cases, sockets may become truly infected, with pus, local swelling and perhaps lymphadenopathy. This is usually localised to the socket and can be managed in the same way as a dry socket, although antibiotics may be necessary in some instances. A radiograph

should be taken to exclude the presence of a retained root or sequestered bone. Positive evidence of such material in the socket indicates a need for curettage of the socket.

Damage to soft tissues. Crush injuries can occur to soft tissues when a local or general anaesthetic has been used and the patient does not respond to the stimulus and, therefore, inform the operator. This may happen to the lower anaesthetized lip when extracting the upper tooth; the lip can be crushed between forceps and teeth if it is not rotated out of the way.

Damage to nerves. Paraesthesia or anaesthesia can result from damage to the nerves in the intradermal canal during extraction of the lower third molars.

Opening of the maxillary sinus. Creation of a communication between the oral cavity and maxillary sinus, an oroantral fistula (OAF), may result during extraction of the upper molar teeth.

Loss of a tooth. A whole tooth may occasionally be displaced into the maxillary sinus, when it is managed as for displacement of a root fragment. A tooth may also be lost into the infratemporal fossa or the tissue spaces about the jaws, but this usually only occurs when mucoperiosteal flaps are raised.

Loss of a tooth fragment. Typically, a fractured palatal root of the upper molar tooth is inadvertently pushed into the maxillary sinus by the misuse of elevators. Rarely, a fragment may be lost elsewhere, such as into the inferior alveolar canal.

Fracture of the maxillary tuberosity. Fracture of the maxillary tuberosity can result from the extraction of the upper posterior molar teeth.

Fracture of a jaw. A fracture of the jaw is a rare event and is most likely to be the result of application of excessive force in an uncontrolled way. More commonly, small fragments of alveolar bone are fractured, which may be attached to the tooth root. Any loose fragments should also be removed.

Dislocation of the mandible. Dislocation may occur when extracting the lower teeth if the mandible is not adequately supported. It is more likely to occur under general anaesthesia and should be reduced immediately.

Displacement of a tooth into the airway. The airway is at risk when extracting teeth of a patient in the supine position. It can be protected when the patient is being treated under general anaesthesia but not when the patient is conscious or being treated under conscious sedation. It is, therefore, essential that an assistant is present and high velocity suction and an appropriate instrument for retrieval of any foreign body are immediately available. A chest radiograph is essential if a lost tooth cannot be found, to exclude inhalation.

Surgical emphysema. Air may enter soft tissues, producing a characteristic crackling sensation on palpation. However, this is unlikely if a mucoperiosteal flap has not been raised. Air-rotor dental drills should not be used during surgery because they may force air under soft tissue flaps.

The patient should be reassured and antibiotics prescribed.

Knowledge level control

1. The structure of the mouth.
2. Terms of teeth eruption in the temporary and permanent occlusion.
3. Features of the development and structure of the upper jaw.
4. Features of the development and structure of the lower jaw.
5. Features of the development and structure of the temporomandibular joint.
6. Features of the development and structure of the masticatory and facial muscles.
7. Features of the development and structure of the salivary glands.
8. Features of the blood supply and innervation of soft tissues and jaws.
9. Indications and contraindications to the tooth extraction.
10. Armamentarium for the tooth extraction.
11. Peculiarities of the preparation of the patient for the tooth extraction.
12. Peculiarities of the primary teeth extraction.
13. Peculiarities of the permanent teeth extraction.
14. Preoperative tooth extraction complications, their prevention.

15. Postoperative tooth extraction complications (hemorrhage, alveolitis, socket pain), their prevention and treatment.

Tests

1. The face develops of the following arch:
 - A. First branchial arch
 - B. Second branchial arch
 - C. Third branchial arch
 - D. Fourth branchial arch
 - E. Fifth branchial arch.

2. In what period do the maxillary and frontal processes complete their fusion?
 - A. By the 8th week of prenatal period
 - B. By the 4th week of prenatal period
 - C. By the 8th week of postnatal period
 - D. By the 6-month of postnatal period
 - E. By the 2nd week of prenatal period.

3. A 16-year-old boy applied to the dentist for a surgical treatment of the oral cavity. The 36 tooth is fully destroyed. What anesthesia is better to use for anesthetizing during the extraction of the 36 tooth?
 - A. Torus anesthesia
 - B. Infiltration anesthesia
 - C. Mental anesthesia
 - D. Mandibular anesthesia
 - E. Topical anesthesia.

4. During the extraction of 17 tooth because of the chronic granulomatous periodontitis a doctor applied the block anesthesia, in particular, tuberosity anesthesia. What nerves will be blocked during this anesthesia?
 - A. Posterior nervi alveolaris
 - B. Nervus incisivus
 - C. Anterior nervi alveolaria
 - D. Upper dental interlacing
 - E. Nervus mandibularis.

5. The extraction of the 46 tooth is recommended to the patient. The crown of the tooth is remained; opening of the mouth is free. Choose the optimal type of anaesthesia and the medical instrumentation.
 - A. Torus anaesthesia; lower molars forceps
 - B. Torus anaesthesia, direct and angular elevator, incisors and canine's forceps
 - C. Mandibular anaesthesia direct and angular elevator, incisors and Canine's forceps
 - D. Mandibular and cheek anaesthesia; direct elevator, lower third molars forceps, incisors and canine's forceps
 - E. Bershe-Dubov anaesthesia, direct and angular elevator.

PRACTICAL LESSON № 2

Theme. Odontogenic and non-odontogenic, acute and chronic periostitis of the jaws. Clinic, diagnostics, differential diagnostics. Surgical treatment. Complications, their treatment and prevention.

Aim of the lesson. To study with students the features of etiology, pathogenesis, clinical course, treatment and complication of periostitis of the jaws in children.

Control of the initial level of knowledge

1. Anatomy and physiology of the primary and permanent teeth, jaw bones in children.
2. The ways of infection spreading in maxillo-facial region in children.
3. An importance of the early diagnosis and treatment of the inflammatory processes of MFR in children.

Content of the lesson

Periostitis is a medical condition caused by inflammation of the periosteum, a layer of the connective tissue that surrounds bone.

The classification of periostitis:

By clinical course:

- Acute (serous, purulent)
- Chronic (hyperplastic, ossifying)

By the etiology:

- Odontogenic;
- Nonodontogenic (posttraumatic, by spreading, haematogenic, lymphogenic, stomatogenic);

By the type of infection:

- Specific;
- Non-specific.

Acute odontogenic serous periostitis.

Rarely this form of periostitis is diagnosed in children due to its fast develop into the festering form (1-2 days).

Complaints: - tooth pain during chewing;

- worsening of the self condition (decreasing of the appetite and disturbances of the night sleep);
- painful edematous swelling of the cheek and the mucosa of alveolar process.

Clinic:

- asymmetry of the face due to edema of the soft tissues around the painful thickening of the periosteum;
- “Causal” tooth is injured by periodontitis;
- Discoloration of the blasted crown of the tooth;
- Tenderness to percussion;
- Mucogingival fold is filled-in and swollen from the one side (mainly on the vestibular), infiltrated, painful, reddening of the mucosa is observed;
- No fluctuation.
- No specific roentgenologic picture.

Treatment: - the first of all a dentist should make the decision regarding the “causal” tooth, depending on its functional status, stage of the root resorption at the primary tooth, possibility of the conservative treatment of the permanent tooth. If there is no effectiveness of conservative therapeutic treatment, the tooth should be extracted;

- the relief is not always present after the tooth extraction; that is why the periostotomy and drainage (for 3-4 days) supposed to be carried out with the tooth extraction; the periostotomy is provided for decreasing of the tissue pressure in the inflamed area;
- antimicrobial and antihistaminic drugs.

Complication - the acute suppurative odontogenic periostitis.

Acute odontogenic suppurative periostitis.

This form is mainly observed in 6-8 years old children with mixed dentition.

Complaints: - facial deformation in the lower or upper jaw area;

- difficulties during chewing on the injured side;
- general intoxication (body temperature rises, decreasing of the appetite, disturbances of the night sleep);
- limited mouth opening;
- pain during swallowing, etc.

Clinical picture: - facial asymmetry due to tissue edema with a slightly skin reddening;

- limited mouth opening due to a painful tissue edema;
- filled- in mucogingival fold on vestibular side on level of “causal” tooth and of the 1-2 adjacent teeth; mucosa is reddened and swelled, frank fluctuation;
- “causal” tooth is destroyed, mobile;
- slight tenderness to percussion;
- regional lymphadenitis on the injured side
- when the roots of primary teeth are on the resorption stage, the obvious clinical features are not revealed during observation. The infiltration of the periosteum is located closely to the marginal gingival side. That is why abscesses in such cases are revealed subgingivally.

Differential diagnosis should be carried out with chronic periodontitis, lymphadenitis, osteomyelitis, and purulent radicular and follicular cysts of the jaw, malignant tumors.

Treatment.

The treatment should be started as soon as possible – straight after the setting of the diagnosis. The periostotomy and drainage should be provided with a primary tooth extraction. When the permanent tooth is involved into the inflammatory process the drainage of pus through the root canal should be performed. If there are evidences of body’s weakness, frank local clinical features of periostitis, presence of allergic reactions and chronic diseases in anamnesis, the child should be hospitalized.

Surgical treatment:

- the incision during periostotomy should be provided parallel to the mucogingival fold and the lower or upper of the latter one (depending on the jaw);
- when the palatal periostitis is observed, the triangle or oval mucoperiosteum flap excision should be performed, the drainage is not needed.

After the surgical intervention the dentist prescribes the mouth bath with antiseptics, dymexid compression with furaceline and physiotherapeutic procedures.

Complication: osteomyelitis, abscess and phlegmon of the soft tissues.

Chronic periostitis.

This form is rarely observed in children. Mainly it occurs as the result of untreated inflammatory process in the periodontum during 10-14 days from the beginning of the disease. The acute trauma of the jaw could be the reason of nonodontogenic chronic inflammation of the periosteum.

There are *two forms* of the chronic periostitis:

- Common;
- Ossifying (elder aged children).

Complaints: - unpainful or slightly painful deformation of the certain area of the jaw.

Clinical picture: - a changed facial configuration due to enlargement of the certain area of the jaw with a normal skin above it;

- painless or slightly painful palpation, enlargement of the lymphatic nodules could be observed;
- free mouth opening;

- cyanosis of the mucosa above the filled-in mucogingival fold;
- thickening of the alveolar process during the palpation is observed;

If the adequate treatment is not provided, the common periostitis will transform into the ossifying.

Roentgenologically on the common stage the shade of the periosteum thickening of the bone on the jaw edge is observed. On the X-ray of the ossifying form the areas with new developed bone are present.

Dif. Diagnosis: with fibrous osteodysplasia, giant-cell tumor, chronic osteomyelitis, tuberculosis.

Treatment

- Surgical incision of the infiltrate should be performed to the bone in the area of the enlarged periosteum;
- The wound should be drained (5-7 days) and irrigated with antiseptics;
- Physiotherapeutic procedures;
- Surgical leveling of the enlarged part of the bone when ossifying form is present;
- Extraction or treatment of the “causal” tooth;
- Symptomatic therapy.

Knowledge level control

1. The modern concerns on the etiology and pathogenesis of acute and chronic periostitis.
2. Clinical forms of odontogenic periostitis in children, their diagnosis.
3. Differential diagnosis of periostitis with other diseases of the MFA in children.
4. Medical and surgical methods of treatment.
5. Indications for the surgical treatment.
6. Prognosis of the disease.
7. Prevention of acute purulent periostitis in children.

Tests

1. A 8-year-old child has the edema in undermandibular area, a monouth is opened on 1.5 sm, the subsequent opening is painful, the body temperature is 37.6 C, a transitional fold is smoothed out vestibular, swollen, bloodshot. There is fillings in 84, 85 teeth, percussion is painless. the 84 tooth is mobile (I degree). What is the most probable diagnosis?

- A. Acute odontogenic periostitis
- B. Exacerbation of chronic periodontitis
- C. Chronic odontogenic periostitis
- D. Chronic odontogenic osteomyelitis
- E. Chronic odontogenic osteomyelitis.

2. A 10-year-old child complains of the edema and pain in the right cheek, general weakness, and increase of body temperature. Objectively: tenderness to the presence of edeme in the lower third of the rihgt cheek, a slight swelling of the skin, no change in color, undertakes ion a fold. Intraoral examination: The 46 tooth on the third is blasted by a caries, the cavity of the tooth is opened, the probing is painless, percussion is painful. Transitional fold in the area of 46, 85 and 84 teeth was smoothed out, swollen, fluctuation wasn't revealed. Define the diagnosis.

- A. Acute serous periostitis
- B. Acute purulent periostitis
- C. Chronic periositis
- D. Acute serous periodontitis
- E. Acute odontogenic osteomyelitis.

3. 12 hours ago a slight swelling of the left cheek appeared in a 13-year-old boy. During examination: Asymetry of the face because of slight swelling of soft tissue of the left cheek, there is a tenderness on to palpation. During the intraoral examination hyperemic and edema of mucus shell of gums from a

vestibular side in the area of the 26 tooth was found out. The 26 tooth is blasted, percussion is sharply positive, the 26 is mobile (I degree). What is the most probable diagnosis?

- A. Odontogenic acute periostitis
- B. Non-odontogenic acute periostitis
- C. Chronic odontogenic periostitis
- D. Odontogenic acute osteomyelitis
- E. Odontogenic acute lymphadenitis.

4. A child of 8 years old complains about a sharp pain in a lower jaw on the left. With diminishing of permanent pain the edema appeared after 3 days. Objectively: the general condition of average weight, the temperature is nearly 38.2 C. The edema of the cheek area is expressed. Root of the 74, 75, 36 without pathology. A transitional fold from a vestibular side is smoothed out through subperiosteum inflammatory symptom of fluctuation. What is the most probable diagnosis?

- A. Acute purulent periostitis
- B. Aggravation of chronic periodontitis
- C. Acute serous periostitis
- D. Acute odontogenic osteomyelitis
- E. Chronic periodontitis.

5. A 12-year-old boy complains of pain and edema in the infraorbital area. After examination a dentist diagnosed the odontogenic acute purulent periostitis. The periostotomy was indicated. Define the place of incision.

- A. Linear incision in the greatest place of protrusion
- B. Triangle mucoperiosteum flap excision
- C. Oval mucoperiosteum flap excision
- D. Above transitional fold
- E. Below transitional fold.

PRACTICAL LESSON № 3

Theme. Acute odontogenic osteomyelitis of the jaws in children. Acute non-odontogenic osteomyelitis of the jaws in children. Chronic osteomyelitis of the jaws in children.

Aim of the lesson. To study the modern concerns about pathogenesis, clinical picture, diagnosis, treatment of the acute and chronic osteomyelitis of the upper and lower jaws in children.

Control of the initial level of knowledge

1. Anatomy and physiology of the primary and permanent teeth, jaw bones in children.
2. The ways of infection spreading in maxillofacial region in children.
3. An importance of the early diagnosis and treatment of the inflammatory processes of MFR in children.
4. The reasons of the nonodontogenic osteomyelitis development.
5. An importance of the early diagnostic and correct treatment of the acute nonodontogenic inflammatory processes of MFR.

Content of the lesson

Osteomyelitis is a purulent, necrotic, infectious- allergic inflammatory process in a bone that occurred due to the influence of exo- and endogenic factors on the base of previous sensibilization and

secondary immunosuppression of the organism. Osteomyelitis is accompanied by necrosis of the bone tissue. Osteomyelitis is defined as an inflammation of the bone marrow with a tendency to progression. This is what differentiates it in the jaw from the ubiquitous dentoalveolar abscess, "dry socket" and "osteitis," seen in infected fractures.

Pathogenesis. In the maxillofacial region, osteomyelitis primarily occurs as a result of contiguous spread of odontogenic infections or as a result of trauma. Primary hematogenous osteomyelitis is rare in the maxillofacial region, generally occurring in the very young children. The adult process is initiated by an inoculation of bacteria into the jawbones. This can occur with the extraction of teeth, root canal therapy, or fractures of the maxilla or mandible. This initial insult results in a bacteria-induced inflammatory process or a cascade. With inflammation there is hyperemia and increased blood flow to the affected area. Additional leukocytes are recruited to this area to fight off infection. Pus is formed when there is an overwhelming supply of bacteria and cellular debris that cannot be eliminated by the body's natural defense mechanisms. When the pus and subsequent inflammatory response occur in the bone marrow, an elevated intramedullary pressure is created which further decreases the blood supply to this region. The pus can travel via Haversian and Volkmann's canals to spread throughout the medullary and cortical bones. Once the pus has perforated the cortical bone and collects under the periosteum, the periosteal blood supply is and this further aggravates the local condition. The end point occurs when the pus enters the soft tissues either by intraoral or extraoral fistulas.

Classification

Osteomyelitis of maxillofacial area in children is classified in the following way:

1. By the spreading of infection:

- Odontogenic;
- Nonodontogenic :
 - a) vascular: - hematogenous; - lymphogenous;
 - b) stomatogenous;
 - c) post-traumatic;
 - d) contiguous.

2. By the type of infection:

- specific (actinomycetous, syphilitic, tuberculous) is rarely observed in children;
- nonspecific (commonplace), caused by mixed microbial infection.

3. By the course of a disease:

- Acute;
- Primary chronic;
- Chronic as the result of acute osteomyelitis:

- a) destructive form ;
 - b) productive or hyperplastic form;
 - c) destructive-productive form;
- Exacerbation.

4. By the anatomy: - Osteomyelitis of the upper or lower jaw (with clear localization of the process);

- Osteomyelitis of the other bones of maxillofacial area.

5. By the spreading: - localized;

- generalized.

Clinical Presentation. Very often, as with any infection, the patient with osteomyelitis of the maxillofacial region will present with classic symptoms:

- Pain
- Swelling and erythema of overlying tissues in the region of causal and adjacent teeth
- Deformation of the alveolar process from the both sides
- The pus is observed during the palpation
- The causal tooth is injured with periodontitis
- Mobility of the adjacent teeth (2-3)

- Adenopathy
- Fever
- Paresthesia of the inferior alveolar nerve (Vensan's symptom)
- Trismus
- Malaise
- Fistulas, abscesses, phlegmon of the soft tissues

The pain in osteomyelitis is often described as a deep and boring pain, which is often out of proportion to the clinical picture. In acute osteomyelitis it is very common to see swelling and erythema of the overlying tissues, which are indicative of the cellulitic phase of the inflammatory process of the underlying bone. Fever often accompanies acute osteomyelitis, whereas it is relatively rare in chronic osteomyelitis. Paresthesia of the inferior alveolar nerve is a classic sign of a pressure on the inferior alveolar nerve from the inflammatory process within the medullary bone of the mandible. Trismus may be present if there is inflammatory response in the muscles of mastication of the maxillofacial region. The patient commonly has malaise or a feeling of overall illness and fatigue, which would accompany any systemic infection. Lastly both intraoral and extraoral fistulas are generally present with the chronic phase of osteomyelitis of the maxillofacial region. In the acute phase of osteomyelitis it is naturally to reveal a leukocytosis with a left shift, common in any acute infection. Leukocytosis is relatively uncommon in the chronic phases of osteomyelitis. The patient may also exhibit an elevated erythrocyte sedimentation rate (ESR) and C-reactive protein (CRP). Both the ESR and CRP are very sensitive indicators of inflammation in the body and they are very nonspecific. Therefore, their main use is to follow the progress of the osteomyelitis.

Nearly all patients will have a form of maxillofacial imaging. The orthopantomogram view is indispensable in the initial evaluation of osteomyelitis. One must bear in mind that radiographic images lag behind the clinical presentation since the cortical involvement is required for any change to be evident. Therefore, it may take several weeks before the bony changes appear radiographically. Hence, it is possible to see a patient with acute osteomyelitis that has a normal-appearing orthopantomogram. However, one can often see the appearance of "moth-eaten" bone or sequestrum of bone, which is the classic appearance of osteomyelitis.

Computerized tomography (CT) scans have become the standard in evaluating the maxillofacial pathology such as osteomyelitis. They provide a three-dimensional imaging not available on an orthopantomogram view.

Dif. Diagnosis: with odontogenic and nonodontogenic abscesses and phlegmons, sialoadenitis, specific processes, periostitis, Ewing sarcoma, suppurative jaw cysts.

Hematogenic osteomyelitis.

This type of osteomyelitis occurs in 7 % of all cases of osteomyelitis in kids; more often present on the upper jaw in kids of 1-2 years of age. Staphylococcus is the main etiological factor which leads to hematogenic osteomyelitis. Entry of infection are umbilical sepsis, purulent dermal lesions, microtraumas of mucosa, chroniosepsis, otitis, the disturbance of the nursing care of the child due to mother's mastitis. There is an acute beginning of the disease with frank intoxication. The symptoms of the general malaise predominate over the local ones. By the clinical course there are three forms of the hematogenic osteomyelitis:

- toxic;
- septicopyemic form;
- focal (rarely present in kids)

Toxic form is characterized by tempestuous course – high temperature, severe intoxication of the organism, tachycardia, hypo- and tachypnoe, left shift, leucocytosis, anemia, increasing of the ESR in the blood. The symptoms of the jaw involvement appear only on the fourth- sixth days after the onset of the disease.

Septicopyemic form also is characterized by rapid course and violent worsening of the general condition of the child. But in spite of the toxic form the local signs appear quickly.

Microbial etiology of acute hematogenous osteomyelitis

While a variety of bacterial pathogens may be involved, *S. aureus* is the preeminent pathogen and is responsible for 70–90% of AHO infections in children. Other etiological agents, in no particular order, include *Streptococcus pyogenes*, *Streptococcus pneumoniae*, Group B streptococci (in infants), coagulase-negative staphylococci enteric Gram-negative bacilli (especially *Salmonella* spp. in individuals with sickle cell disease) and anaerobic bacteria. *Haemophilus influenzae* type b (Hib) was a common cause of childhood osteomyelitis, but its prevalence has been abated by introduction of the Hib conjugate vaccine. Organisms such as *Mycobacterium*, *Bartonella*, fungi (*Histoplasma*, *Cryptococcus* and *Blastomyces*), *Candida* and *Coxiella* are unusual causes of osteomyelitis, generally seen in patients with specific risk factors, most notably travel to or residence in geographic regions in which the offending pathogens are endemic and/or immunosuppression. It is also important to note that despite the increasing use of more sensitive diagnostic techniques that are less reliant on culture of the offending bacterium, most notably PCR, the etiology of AHO in children remains unknown in a significant number of cases.

Manifestation.

Most children and adolescents with AHO present with a history of bone pain for several days. The hallmark of AHO pain is its constant nature, with the level of pain increasing gradually. In young children, it is often difficult to elicit pain location, while in older children it is typically more localized. Pain generally leads to restricted use of the involved limb. In all cases, localized bone pain and fever should raise the clinical suspicion of AHO. The classic signs of inflammation (redness, warmth and swelling) do not appear unless the infection has progressed through the metaphyseal cortex into the subperiosteal space. Such progression is more common in infants and young children who have a thinner bone cortex. Elevated erythrocyte sedimentation rate (ESR), elevated C-reactive protein (CRP) and leukocytosis are often seen in AHO, with an elevated CRP being the most sensitive laboratory parameter.

Since physical examination and laboratory tests are suggestive rather than definitive, various imaging techniques have been used to facilitate the diagnosis of osteomyelitis. These include plain radiographs, skeletal scintigraphy, computed tomography (CT) and magnetic resonance imaging (MRI).

Plain radiographs are essential for excluding other diagnoses such as fracture. Although deep soft tissue swelling can be seen radiographically within the first few days of onset, osteopenia or osteolytic lesions from destruction of bone are usually not visible until 2–3 weeks after symptom onset. For this reason, the diagnostic utility of plain radiographs for diagnosing osteomyelitis is limited to those patients with prolonged symptoms and, as noted previously, this is generally not the case in children. As a result, other imaging techniques are more commonly used to diagnose pediatric AHO.

Isolation of the causative organism remains the diagnostic gold standard and is currently the only way to establish a definitive microbiologic diagnosis. In a significant number of cases, it is not possible to establish a definitive bacterial etiology, either because the offending organisms are difficult to cultivate or because empiric antimicrobial therapy has compromised.

When the etiologic agent can be identified, empiric antimicrobial therapy should be adjusted based on the specific susceptibility profile of the offending bacterial strain.

Needle aspiration of the affected bone can be performed using relatively noninvasive procedures in neonates and young children, while older children and adolescents often require more invasive surgical techniques such as drilling or cutting into the bone. Direct inoculation of cultured material into a blood culture bottle increases the probability of recovering a fastidious organism such as *K. Kingae*. Using PCR to identify pathogens from bone specimens is also increasingly common.

Tissue samples should also be sent for histological examination to confirm the diagnosis of osteomyelitis. Acquiring cultures early in the course of AHO is helpful because prolonged empiric antimicrobial therapy decreases the chance of recovering the causative agent. Indeed in a stable patient, if a plan is in place to rapidly obtain tissue cultures, it is our opinion that empiric antibiotic therapy should be delayed until tissue cultures are obtained.

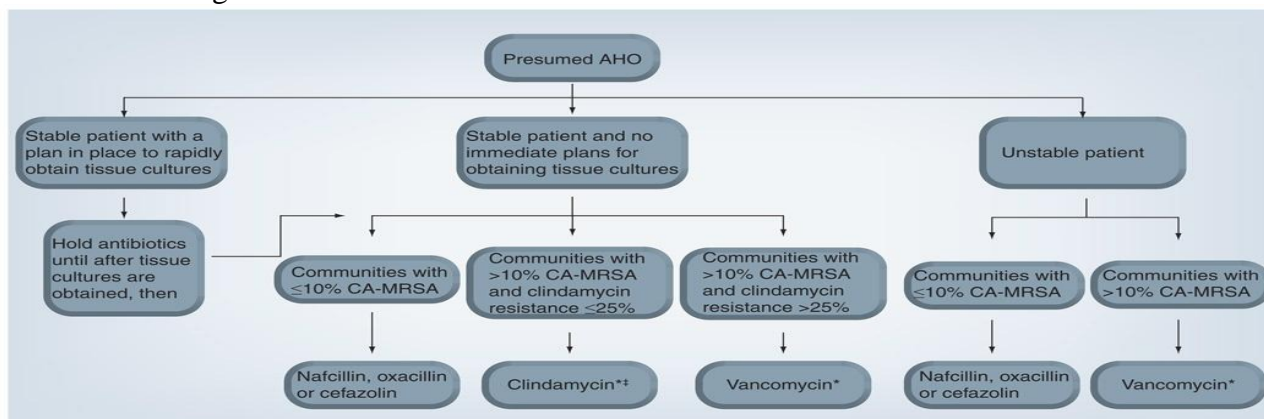
Treatment of acute hematogenous osteomyelitis

The treatment of AHO demands appropriate antimicrobial therapy in all cases and may require surgical incision and drainage. For the reasons discussed earlier, appropriate drainage has become particularly important. Incision and drainage should be performed whenever an abscess (intra-osseous, subperiosteal and/or soft-tissue) exists. Surgical removal of devitalized bone and debridement of affected

soft tissues should be undertaken. Multiple incision and drainage procedures are often necessary in children and adolescents with osteomyelitis, even with appropriate antibiotic therapy. Surgical drainage should also be considered when a child does not respond to empiric antibiotic therapy. In that case, surgical intervention may enhance treatment. In addition, surgical intervention allows for the collection of tissue which can be microbiologically evaluated for unusual etiologies of osteomyelitis, and histologically examined to confirm the diagnosis.

Whether or not surgical intervention is required, the successful treatment of all forms of osteomyelitis requires appropriate antibiotic therapy. Antibiotics that have proven efficacy against *S. aureus* bone and joint infections include nafcillin, clindamycin, first-generation cephalosporins and vancomycin.

It should also be emphasized once again that if cultures yield a definitive diagnosis, antimicrobial treatment should be adjusted immediately based on the susceptibility profile of the offending organism. Figure 1 is an algorithm for the suggested initial antibiotic therapy of AHO in children 3 months of age and older.



Algorithm for the suggested initial antibiotic therapy of acute hematogenous osteomyelitis in children 3 months of age or older

Trimethoprim–sulfamethoxazole (TMP–SMX) has been used successfully for the treatment of skin and soft-tissue infections (SSTIs) caused by CA-MRSA. However, the effectiveness of TMP–SMX in the treatment of MRSA osteomyelitis in children has not been adequately studied. Similarly, doxycycline can be an effective option for the treatment of susceptible MRSA SSTIs in children older than 8 years of age, but its use for the treatment of MRSA osteomyelitis in children remains unstudied. New antimicrobial agents have also become available for the treatment of infections caused by MRSA in recent years. These include linezolid (an oxa-zolidinone antibiotic) and daptomycin (a lipopeptide antibiotic). So far, clinical experience with these drugs in the specific context of bone infection in children is limited, although in one study of 13 children treated with linezolid as step-down or alternative therapy for osteoarticular infections, 11 of the 13 children did well. The mean duration of therapy was 20 days and during the course of therapy, two children developed anemia. Myelosuppression is a known side effect of prolonged therapy with linezolid, as are optical and peripheral neuropathies. For this reason, a treatment course of longer than 21 days is not recommended. This limits the use of linezolid in the treatment of AHO in children, which requires prolonged antimicrobial therapy. Pediatric studies of daptomycin efficacy are lacking. Daptomycin use for AHO in children is limited as MRSA AHO complicated by pneumonia is an increasing problem, and daptomycin is inactivated by lung surfactants and cannot be used to treat such complicated infections. Daptomycin is also known to cause creatinine phosphokinase elevation. Creatinine phosphokinase levels should be monitored closely if daptomycin is used, as dangerous rhabdomyolysis

can occur. Recent studies have found that daptomycin is particularly effective in the specific context of a biofilm and in the treatment of biofilm-associated infections, including those caused by MRSA. This could be particularly important, specifically in the context of chronic osteomyelitis.

Standard therapy for AHO ranges from 4 to 6 weeks in duration. Evidence-based data about the route and duration of antibiotic administration for AHO are limited and criteria establishing when to change from parenteral to oral therapy are undefined. Prolonging antibiotic treatment may be necessary if there is delayed or incomplete surgical evacuation or if there are distant foci of infection (i.e., endocarditis). Interventional radiological placement of indwelling venous catheters in a peripheral vein is readily available, but the costs of catheter placement, home intravenous antibiotics and home nursing care are considerably higher than those required for oral therapy. In addition, complications associated with central venous catheter placement such as bacteremia arising from the indwelling device and line malfunction are relevant considerations. In a review comparing the outcome of a short (<7 days) versus a long (>7 days) course of intravenous treatment for AHO caused primarily by MSSA in children 3 months to 16 years of age, 12 prospective studies revealed an overall cure rate of 95.2% (95% CI: 90.4–97.7) for the short course compared with 98.8% (95% CI: 93.6–99.8) for the longer course at 6 months [26], which is a modest difference in light of the potential complications and costs noted above. In addition, there was no significant difference in therapeutic outcome based on the duration of oral therapy between the two groups.

Children can be effectively treated with sequential parenteral/oral therapy provided several conditions are accepted. Parenteral antibiotics should be given until the child is afebrile and has demonstrated improvement by both physical assessment and laboratory analysis. It is recommended 7–14 days of parenteral therapy for bacteremic patients; a shorter course of intravenous therapy is acceptable for nonbacteremic children. At the outset of treatment, CRP and ESR should be monitored weekly to assess the response to therapy. The CRP typically returns to baseline within a week of effective therapy and is used by many as a marker for the transition from parenteral to oral therapy. A complete blood count should be obtained weekly to evaluate the response to therapy and to monitor for neutropenia, a potential consequence of antibiotic therapy. The total duration of therapy should be based on the resolution of symptoms and normalization of ESR, which typically takes 4–6 weeks. Reliable caregivers must be present and regularly scheduled outpatient follow-up should be arranged. The oral antibiotic must demonstrate excellent bone penetration, have the same degree of antibacterial coverage as the parenteral drug, and the child should have the ability to take oral medications.

Atypical forms of reaction on microorganisms, decreasing of the defense of the child's organism, unreasonable intake of antibiotics, and incorrect treatment of the acute form of odontogenic inflammatory processes may lead to **primary chronic osteomyelitis (osteomyelitis Garre)** development.

The disease mainly occurs in children of 7-12 years old on the mandible in the premolars and molars region. The thickening of the alveolar bone or angle of the jaw is the principal symptom of the disease. The clinical manifestation of the inflammation may be absent or slightly expressed. The solid, painless lesion with unchanged mucosa is revealed during the palpation. The pus is not present in case of excision. On X-ray examination: extension and consolidation of the cortex, small areas of the bony resorption in the marginal region, periosteum thickening are present.

Chronic odontogenic osteomyelitis is a result of an untreatable or incorrectly treatable of acute osteomyelitis which happens after 7-9 days of acute onset. Ch.O.O. mainly develops on the lower jaw in children of 5-10 years old. Exacerbation and long-lasting course are characteristic features of these forms of osteomyelitis:

- Destructive
- Productive
- Destructive-productive

Treatment

The management of osteomyelitis of the maxillofacial region requires both medical and surgical interventions. In rare cases infantile osteomyelitis, intravenous antibiotic therapy alone may eradicate

the disease. Antibiotic therapy is rarely curative in later-onset cases, and the overwhelming majority of osteomyelitis cases surgical intervention.

Clearly the first step in the treatment of osteomyelitis is diagnosing the condition correctly. The tentative diagnosis is made from clinical evaluation, radiographic evaluation, and tissue diagnosis. The clinician must be aware that malignancies can mimic the presentation of osteomyelitis and must be kept in the differential diagnosis until ruled out by tissue histopathology. Tissues from the affected site should be sent for Gram stain, culture, sensitivity, and histopathologic evaluations. The clinical response to the treatment of any patient will be compromised unless altered host factors can be optimized. Medical evaluation and management in defining and treating any immunocompromised state is indicated and often helpful. For example, glucose control in a diabetic patient should be stabilized for best response to therapy.

Empiric antibiotic treatment should be started based on Gram stain results of the exudate or the suspected pathogens likely to be involved in the maxillofacial region. Definitive culture and sensitivity reports generally take several days or longer to be obtained but are valuable in guiding the surgeon to the best choice of antibiotics based on the patient's specific causative organisms. Infectious disease consultation may illustrate the most current antimicrobials and/or regimens.

Surgical Options

Classic treatment is sequestrectomy and saucerization. The aim is to debride the necrotic or poorly vascularized bony sequestra in the infected area and improve blood flow. Sequestrectomy involves removing infected and avascular pieces of bone—generally the cortical plates in the infected area. Saucerization involves the removal of the adjacent bony cortices and open packing to permit healing by secondary intention after the infected bone has been removed. Decortication involves removal of the dense, often chronically infected and poorly vascularized bony cortex and placement of the vascular periosteum adjacent to the medullary bone to allow increased blood flow and healing in the affected area. The key element in the above procedures is determined clinically by cutting back to good bleeding bone. Clinical judgment is crucial in these steps but can be aided by preoperative imaging that shows the bony extent of the pathology. It is often necessary to remove teeth adjacent to an area of osteomyelitis. In removing adjacent teeth and bone the clinician must be aware that these surgical procedures may weaken the jaw bone and make it susceptible to pathologic fracture. Supporting the weakened area with a fixation device (external fixator or reconstruction type plate) and/or placing patient in maxillomandibular fixation is frequently used to prevent pathologic fracture. Some authors have proposed adjunctive treatment methods that deliver high doses of antibiotic to the area using antibiotic impregnated beads or wound irrigation systems.

Resection of the jaw bone has traditionally been reserved as a last-ditch effort, generally after smaller debridements have been performed or previous therapy has been unsuccessful or to remove areas involved with pathologic fracture. This resection is generally performed via an extraoral route, and reconstruction can be either immediate or delayed based on surgeon's preference. Rigid internal fixation has simplified the postoperative course by providing a means for immediate function of the jaws. We believe that early resection and reconstruction shorten the course of treatment. Once the patient develops paresthesia in mandibular osteomyelitis, resection and immediate reconstruction are indicated. At this point preservation of the mandible is highly unlikely and one should attempt to shorten the course of the disease and treatment.

Knowledge level control

1. Etiology, pathogenesis of acute osteomyelitis.
2. Classification of acute osteomyelitis.
3. Peculiarities of the clinical course of acute odontogenic osteomyelitis in children.
4. Diff. diagnosis of acute odontogenic osteomyelitis.
5. The scheme of treatment of acute odontogenic osteomyelitis.
6. Peculiarities of the clinical course of acute osteomyelitis in children.

Etiology, pathogenesis and pathological anatomy of acute hematogenous osteomyelitis of the jaws in children.

7. Classification of hematogenous osteomyelitis in children.
8. Features of the clinical course of acute hematogenous osteomyelitis in children.
9. Differential diagnosis of acute hematogenous osteomyelitis in children.
10. The scheme of treatment of acute hematogenous osteomyelitis.
11. Differential diagnosis of acute hematogenous osteomyelitis. Prognosis, possible complications.
12. Modern classification of chronic osteomyelitis in children. Clinical symptoms of the chronic osteomyelitis in children.
13. Clinical and roentgenological forms of chronic osteomyelitis in children.
14. Modern methods of diagnostic of chronic osteomyelitis in children.
15. Diff. diagnostic of chronic osteomyelitis in children.
16. The scheme of the treatment of chronic osteomyelitis in children.
17. Indications for the surgical treatment of chronic osteomyelitis in children and their terms.
18. Rehabilitation of the patients.

Tests

1. A 4-year-old child come to a doctor complains of the general condition of moderate body temperature 38,5 ° C. OBJECTIVE: Facial asymmetry due to swelling of the right cheek in the lower third of the face and right submandibular area. Open mouth free, thickening of the alveolar process in the region 83,84,85 teeth on both sides. These teeth are moving, percussion sharply positive. What method of treatment is shown in this case?
 - A. Removing the causal tooth to cut the abscesses on both sides of alveolar bone
 - B. To cut the abscesses on both sides of the alveolar bone
 - C. Removing of the causal tooth
 - D. Removing of the causal tooth and cut along the crease of the transition
 - E. Removing of the causal tooth and pro liferatively modified periosteum.

2. 10-year-old boy is sick for 3 days. OBJECTIVE: asymmetrical face, skin bloodshots is not taken in the crease. Open of the mouth is painful, almost in its entirety. 36 tooth previously was treated about periodontitis, the percussion of the 34, 75 and 36 teeth are painful, mucous membrane within 34, 75, 36 hyperemic alveolar process spindly thickened. The diagnosis: acute purulent odontogenic osteomyelitis. The complication of purulent osteomyelitis can be?
 - A. All answers are correct
 - B. Mumps
 - C. Arthritis
 - D. Septic condition
 - E. The transition of the process in acute chronic.

3. A 6-year-old patient. General conditions: average of a face due to the slight swelling of the right cheek in the lower third and right under a jaw area. Opening of the mouth is free, deformation of alveolar chest in the area 83,84,85 teeth on each side. The teeth are mobile, percussion is sharply positive. What is the most credible diagnosis
 - A. Acute odontogenic osteomyelitis
 - B. Phlegmon of under jaw triangle
 - C. Abscess of jaw-tongue groove
 - D. Hematogenic osteomyelitis
 - E. Acute festering periostitis.

4. A girl of 12 years old complained of a slight swelling and pulsating pain in the area of the lower jaw from the right side, the temperature is 39°C. Objectively: considerable asymmetry of the face because of the slight swelling in the area of the lower jaw from the right side and submandibular triangle. Opening of the mouth is painful and restricted. A crown of the 46 tooth is blased. There is a

tenderness to percussion of the 46, 45, 44 teeth which are mobile. Mucosa of the lower jaw from the right side is sharply blushing, bilateral deformation of mandibular alveolar part is clearly marked and palpation of it is painful. Lymphatic nodes are enlarged and sickly during palpation. What is the most reliable diagnosis?

- A. Acute odontogenic osteomyelitis of lower jaw
- B. Osteogenic sarcoma
- C. Acute bacterial submaxillitis
- D. Acute lymphadenitis of the lower jaw
- E. Odontogenic submandibular phlegmon.

5. The boy of 7-year-old complains about a sharp pain in the right area of the lower jaw, general weakness, the boy temperature- 38,5 C, difficulties in swallowing. Objectively: the face is asymmetric because of the edema of the lower third of the right cheek and submandibular area. Intraoral examination: there is the edema of mucus in the area indicated mobile, percussion is sharply positive. Regional lymph nodes are megascopic, sickly. Ventsian symptom takes place. Point the appropriate diagnosis.

- A. Acute odontogenic osteomyelitis of the lower jaw
- B. Acute odontogenic periostitis of the lower jaw
- C. Sharpening of chronic periodontitis
- D. Odontogenic exacerbation lymphadenitis
- E. Odontogenic phlegmon of submandibular area.

PRACTICAL LESSON № 4

Theme. Odontogenic, non-odontogenic abscesses and phlegmons of the maxillofacial area. Classification, clinic and diagnosis depending on the localization of the inflammatory focus. Differential diagnostics. Surgical treatment and its complications. General principles of complex treatment.

Aim of the lesson. To repeat an anatomy of the cellular space of the maxillo-facial area in children. To study diagnosis, clinical course and peculiarities of treatment of abscesses and phlegmons of MFA in children.

Control of the initial level of knowledge:

1. Anatomical and physiological peculiarities of the teeth, jaw bones and soft tissues in children.
2. The ways of the infection spreading into the soft tissues of MFA and neck.
3. Anatomy of the cellular spaces of the MFA and neck in children.

Content of the lesson:

Abscess is the limited purulent dissolution of the soft tissues. The hypoderm is well expressed in children in MFA. It has protective amortisative functions, makes round counters of the face. But due to the lack of the blood supply this hypoderm is involved into the inflammatory processes very often. As a result the cavity is formed and is filled in with the pus.

Phlegmon is spread purulent dissolution of the soft tissues. This condition is an acute, diffuse inflammatory infiltration of the loose connective tissue found underneath the skin. It is believed today that cellulitis and phlegmon are interchangeable terms. The term cellulitis has prevailed so the term phlegmon has been abandoned.

Etiology: causative agent of abscesses and phlegmons is mixed microflora with dominating of *Streptococcus* and *Staphylococcus* in combination with *Escherichia coli* and other kinds of bacilli.

Clinical Presentation. This disease is characterized by edema, headache, and reddish skin. The edema, whose margins are diffuse and not defined, may be present in various areas of the face and its localization depends on the infected tooth respectively. For example, if the mandibular posterior teeth are involved, the edema presents as submandibular, and, in more severe cases, spreads towards the cheek or the opposite side, leading to grave disfigurement of the face. When the infection originates in the maxillary anterior teeth, the edema involves the upper lip, which presents with a characteristic protrusion. In the initial stage, cellulitis feels soft or doughy during palpation, without pus present, while in more advanced stages, a board-like induration appears, which may lead to suppuration. At this stage, the pus is localized in small focal sites in the deep tissue.

Abscesses and phlegmons of odontogenic region appear as the result of infection spreading from the apical region due to exacerbation of chronic periapical inflammation of primary and permanent teeth, suppuration of the radical cysts. Osteomyelitis can be accompanied with abscesses and phlegmons. These pathologies may occur as possible complications of periostitis.

Peculiarities of the clinical course:

1. Soft tissues in children are characterized with the less tightness of fascias and aponeurosis which limit the anatomical space.
2. The hypoderm is more loose.
3. Immaturity of the cellular barrier leads to the infection spreading on the new tissues.
4. Functional lymph system immaturity leads to more frequent lymph nodes involving in the inflammatory process.
5. Facial blood supply is better expressed in comparison with other areas and it has positive and negative (quick infection spreading) sides.
6. Significant pain reactions.
7. Rapid formation of the purulent process (2-3 days).
8. Superficial abscesses and phlegmons are accompanied with well expressed deformation of the face, and deep ones – with disturbances of chewing, swallowing and speech.

Classification:

- Odontogenic,
- Nonodontogenic

Superficial Deep



- | | |
|-----------------------------|-------------------------------|
| - Mental and submental area | - Retroorbital cellular space |
| - Canine fossa | - Subtemporal fossa |
| - Buccal area | - Pterygomandibular space |
| - Temporal area | - Bottom of the oral cavity |
| - Zygomatic area | - Peripharyngeal space |
| - Parotidomasseteric area | - Temporal area |
| - Submandibular area | |
| - Sublingual area | |
| - Alveololingual groove | |

Upper jaw



- Fossa canina (infraorbital area)
- Zygomatic area
- Orbital area
- Temporal fossa
- Subtemporal and pterygopalatal fossae
- Hard and soft palate

Lower jaw

- mental and submental area
- buccal
- submandibular area
- pterygomandibular area
- peripharyngeal
- parotidomasseteric area

Canine Fossa Abscess

Anatomic Location. The canine fossa, in which this type of abscess develops, is a small space between the levator labii superioris and the levator anguli oris muscles.

Etiology. Infected root canals of premolars and especially those of canines of the maxilla are considered to be responsible for the development of abscesses of the canine fossa.

Clinical Presentation. This is characterized by edema, localized in the infraorbital region, which spreads towards the medial canthus of the eye, lower eyelid, and side of the nose as far as the corner of the mouth. There is also obliteration of the nasolabial fold, and somewhat of the mucolabial fold.

The edema at the infraorbital region is painful during palpation, and later on the skin becomes taut and shiny due to suppuration, while its color is reddish.

Treatment. The incision for drainage is performed intraorally at the mucobuccal fold (parallel to the alveolar bone), in the canine region. A hemostat is then inserted, which is placed at the depth of the purulent accumulation until it comes into contact with bone, while the index finger of the nondominant hand palpates the infraorbital margin. Finally, a rubber drain is placed, which is stabilized with a suture on the mucosa.

Buccal Space Abscess

Anatomic Location. The space in which this abscess develops is between the buccinator and masseter muscles. Superiorly, it communicates with the pterygopalatine space; inferiorly with the pterygomandibular space. The spread of pus in the buccal space depends on the position of the apices of the responsible teeth relative to the attachment of the buccinator muscle.

Etiology. The buccal space abscess may originate from infected root canals of posterior teeth of the maxilla and mandible.

Clinical Presentation. It is characterized by swelling of the cheek, which extends from the zygomatic arch as far as the inferior border of the mandible, and from the anterior border of the ramus to the corner of the mouth. The skin appears taut and red, with or without fluctuation of the abscess, which, if neglected, may result in spontaneous drainage.

Treatment. Access to the buccal space is usually intraoral for three main reasons:

1. Because the abscess fluctuates intraorally in the majority of cases.
2. To avoid injuring the facial nerve.
3. For esthetic reasons.

The intraoral incision is made at the posterior region of the mouth, in an anteroposterior direction and very carefully in order to avoid injury of the parotid duct. A hemostat is then used to explore the space thoroughly. An extraoral incision is made when intraoral access would not ensure adequate drainage, or when the pus is deep inside the space. The incision is made approximately 2 cm below and parallel to the inferior border of the mandible.

Infratemporal Abscess

Anatomic Location. The space in which this abscess develops is the superior extension of the pterygomandibular space. Laterally, this space is bounded by the ramus of the mandible and the temporalis muscle, while medially, it is bounded by the medial and lateral pterygoid muscles, and is continuous with the temporal fossa. Important anatomic structures, such as the mandibular nerve, mylohyoid nerve, lingual nerve, buccal nerve, chorda tympani nerve, and the maxillary artery, are found in this space. Part of the pterygoid venous plexus is also found inside this space.

Etiology. Infections of the infratemporal space may be caused by infected root canals of posterior teeth of the maxilla and mandible, by way of the pterygomandibular space, and may also be the result of a posterior superior alveolar nerve block and an inferior alveolar nerve block.

Clinical Presentation. Trismus and pain during opening of the mouth with lateral deviation towards the affected side, edema at the region anterior to the ear which extends above the zygomatic arch, as well as edema of the eyelids are observed.

Treatment. The incision for drainage of the abscess is made intraorally, at the depth of the mucobuccal fold, and, more specifically, laterally (buccally) to the maxillary third molar and medially to the coronoid process, in a superoposterior direction. A hemostat is inserted into the suppurated space,

in an superior direction. Drainage of the abscess may be performed extraorally in certain cases. The incision is performed on the skin in a superior direction, and extends approximately 3 cm. The starting point of the incision is the angle created by the junction of the frontal and temporal processes of the zygomatic bone. Drainage of the abscess is achieved with a curved hemostat, which is inserted through the skin into the purulent accumulation.

Temporal Abscess

Anatomic Location. The temporal space is the superior continuation of the infratemporal space. This space is divided into superficial and deep temporal spaces. The superficial temporal space is bounded laterally by the temporal fascia and medially by the temporalis muscle, while the deep temporal space is found between the medial surface of the temporalis muscle and the temporal bone.

Etiology. Infection of the temporal space is caused by the spread of infection from the infratemporal space, with which it communicates.

Clinical Presentation. It is characterized by painful edema of the temporal fascia, trismus (the temporalis and medial pterygoid muscles are involved), and pain during palpation of the edema.

Treatment. The incision for drainage is performed horizontally, at the margin of the scalp hair and approximately 3 cm above the zygomatic arch. It then continues carefully between the two layers of the temporal fascia as far as the temporalis muscle. A curved hemostat is used to drain the abscess.

Mental Abscess

Anatomic Location. The accumulation of pus in this space is located at the anterior region of the mandible, near the bone, and, more specifically, underneath the mentalis muscle, with spread of the infection towards the symphysis menti.

Etiology. The infection is usually the result of infected mandibular anterior teeth (incisors).

Clinical Presentation. Firm and painful swelling in the area of the chin is observed, while later the skin becomes shiny and red.

Treatment. The incision for drainage of the abscess may be performed at the depth of the mucobuccal fold, if the abscess fluctuates intraorally. If the pus has spread extraorally, though, an incision is made on the skin, parallel to the inferior border of the chin, 1–1.5 cm posteriorly. After drainage is complete, a rubber drain is placed.

Submental Abscess

Anatomic Location. The submental space in which this abscess develops is bounded superiorly by the mylohyoid muscle, laterally and on both sides by the anterior belly of the digastric muscle, inferiorly by the superficial layer of the deep cervical fascia that is above the hyoid bone, and finally, by the platysma muscle and overlying skin. This space contains the anterior jugular vein and the submental lymph nodes.

Etiology. Infection of the submental space usually originates in the mandibular anterior teeth or is the result of spread of infection from other anatomic spaces (mental, sublingual, submandibular).

Clinical Presentation. The infection presents as an indurated and painful submental edema, which later may fluctuate or may even spread as far as the hyoid bone.

Treatment. After local anesthesia is performed around the abscess, an incision on the skin is made beneath the chin, in a horizontal direction and parallel to the anterior border of the chin. The pus is then drained in the same way as in the other areas.

Sublingual Abscess

There are two sublingual spaces above the mylohyoid muscle, to the right and left of the midline. These spaces are divided by dense fascia. Abscesses formed in these spaces are known as sublingual abscesses.

Anatomic Location. The sublingual space is bounded superiorly by the mucosa of the floor of the mouth, inferiorly by the mylohyoid muscle, anteriorly and laterally by the inner surface of the body of the mandible, medially by the lingual septum, and posteriorly by the hyoid bone. This space contains the submandibular duct (Wharton's duct), the sublingual gland, the sublingual and lingual nerve, terminal branches of the lingual artery, and part of the submandibular gland.

Etiology. The teeth that are most commonly responsible for infection of the sublingual space are the mandibular anterior teeth, premolars and the first molar, whose apices are found above the

attachment of the mylohyoid muscle. Also, infection may spread to this space from other contiguous spaces with which it communicates (submandibular, submental, lateral pharyngeal).

Clinical Presentation. The abscess of the sublingual space presents with characteristic swelling of the mucosa of the floor of the mouth, resulting in elevation of the tongue towards the palate and laterally.

The mandibular lingual sulcus is obliterated and the mucosa presents a bluish tinge. The patient speaks with difficulty, because of the edema, and movements of the tongue are painful.

Treatment. The incision for drainage is performed intraorally, laterally, and along Wharton's duct and the lingual nerve. In order to locate the pus, a hemostat is used to explore the space inferiorly, in an anteroposterior direction and beneath the gland. After drainage is complete, a rubber drain is placed.

Submandibular Abscess

Anatomic Location. The submandibular space is bounded laterally by the inferior border of the body of the mandible, medially by the anterior belly of the digastric muscle, posteriorly by the stylohyoid ligament and the posterior belly of the digastric muscle, superiorly by the mylohyoid and hyoglossus muscles, and inferiorly by the superficial layer of the deep cervical fascia. This space contains the submandibular salivary gland and the submandibular lymph nodes.

Etiology. Infection of this space may originate from the mandibular second and third molars, if their apices are found beneath the attachment of the mylohyoid muscle. It may also be the result of spread of infection from the sublingual or submental spaces.

Clinical Presentation. The infection presents as moderate swelling at the submandibular area, which spreads, creating greater edema that is indurated and redness of the overlying skin. Also, the angle of the mandible is obliterated, while pain during palpation and moderate trismus due to involvement of the medial pterygoid muscle are observed as well.

Treatment. The incision for drainage is performed on the skin, approximately 1 cm beneath and parallel to the inferior border of the mandible. During the incision, the course of the facial artery and vein (the incision should be made posterior to these) and the respective branch of the facial nerve should be taken into consideration. A hemostat is inserted into the cavity of the abscess to explore the space and an attempt is made to communicate with the infected spaces. Blunt dissection must be performed along the medial surface of the mandibular bone also, because pus is often located in this area as well. After drainage, a rubber drain is placed.

Submasseteric Abscess

Anatomic Location. The space in which this abscess develops is cleft-shaped and is located between the masseter muscle and the lateral surface of the ramus of the mandible. Posteriorly it is bounded by the parotid gland, and anteriorly it is bounded by the mucosa of the retromolar area.

Etiology. Infection of this space originates in the mandibular third molars (pericoronitis), and in rare cases because of migratory abscesses.

Clinical Presentation. It is characterized by a firm edema that is painful to pressure in the region of the masseter muscle, which extends from the posterior border of the ramus of the mandible as far as the anterior border of the masseter muscle. Also, severe trismus and an inability to palpate the angle of the mandible are observed. Intraorally, there is edema present at the retromolar area and at the anterior border of the ramus. This abscess rarely fluctuates, while it may present generalized symptoms.

Treatment. Treatment of this abscess is basically intraoral, with an incision that begins at the coronoid process and runs along the anterior border of the ramus towards the mucobuccal fold, approximately as far as the second molar. The incision may also be performed extraorally on the skin, beneath the angle of the mandible. In both cases, a hemostat is inserted, which proceeds as far as the center of suppuration and until it comes into contact with bone. Because access is distant from the purulent accumulation, often it is difficult to drain the area well, resulting in frequent relapse.

Pterygomandibular Abscess

Anatomic Location. This space is bounded laterally by the medial surface of the ramus of the mandible, medially by the medial pterygoid muscle, superiorly by the lateral pterygoid muscle, anteriorly by the pterygomandibular raphe, and posteriorly by the parotid gland. The pterygomandibular

space contains the mandibular neurovascular bundle, lingual nerve, and part of the buccal fat pad. It communicates with the pterygopalatal, infratemporal, submandibular, and lateral pharyngeal spaces.

Etiology. An abscess of this space is caused mainly by infection of mandibular third molars or the result of an inferior alveolar nerve block, if the penetration site of the needle is infected (pericoronitis).

Clinical Presentation. Severe trismus and slight extraoral edema beneath the angle of the mandible are observed. Intraorally, edema of the soft palate of the affected side is present, as is displacement of the uvula and lateral pharyngeal wall, while there is difficulty in swallowing.

Treatment. The incision for drainage is performed on the mucosa of the oral cavity and, more specifically, along the mesial temporal crest. The incision must be 1.5 cm long and 3–4 mm deep. A curved hemostat is then inserted, which proceeds posteriorly and laterally until it comes into contact with the medial surface of the ramus. The abscess is drained, permitting the evacuation of pus along the shaft of the instrument.

Lateral Pharyngeal Abscess

Anatomic Location. The lateral pharyngeal space is conical shaped, with the base facing the skull while the apex faces the carotid sheath. It is bounded by the lateral wall of the pharynx, the medial pterygoid muscle, the styloid process and the associated attached muscles and ligaments, and the parotid gland. The lateral pharyngeal space contains the internal carotid artery, the internal jugular vein with the respective lymph nodes, the glossopharyngeal nerve, hypoglossal nerve, vagus nerve, and accessory nerve. It communicates directly with the submandibular space, as well as with the brain by way of foramina of the skull.

Etiology. Infections of this space originate in the region of the third molar and are the result of spread of infection from the submandibular and pterygomandibular spaces.

Clinical Presentation. Extraoral edema at the lateral region of the neck that may spread as far as the tragus of the ear, displacement of the pharyngeal wall, tonsil and uvula towards the midline, pain that radiates to the ear, trismus, difficulty in swallowing, significantly elevated temperature, and generally malaise are noted.

Retropharyngeal Abscess

Anatomic Location. The retropharyngeal space is located posterior to the soft tissue of the posterior wall of the pharynx and is bounded anteriorly by the superior pharyngeal constrictor muscle and the associated fascia, posteriorly by the prevertebral fascia, superiorly by the base of the skull, and inferiorly by the posterior mediastinum.

Etiology. Infections of this space originate in the lateral pharyngeal space, which is close by.

Clinical Presentation. The same symptoms as those present in the lateral pharyngeal abscess appear clinically, with even greater difficulty in swallowing though, due to edema at the posterior wall of the pharynx. If it is not treated in time, there is a risk of:

✓ Obstruction of the upper respiratory tract, due to displacement of the posterior wall of the pharynx anteriorly.

✓ Rupture of the abscess and aspiration of pus into the lungs, with asphyxiation resulting.

✓ Spread of infection into the mediastinum.

Treatment. Therapy entails drainage through the lateral pharyngeal space, which is where the infection usually begins. Administration of antibiotics is mandatory.

Parotid Space Abscess

Anatomic Location. The space in which this abscess develops is located in the area of the ramus of the mandible and, more specifically, between the layers of the fascia investing the parotid gland. It communicates with the lateral pharyngeal and the submandibular spaces. It contains the parotid gland and its duct, the external carotid artery, the superficial temporal and facial artery, the retromandibular vein, the auriculotemporal nerve, and the facial nerve.

Etiology. Infection of this space originates from odontogenic migratory infections of the lateral pharyngeal and submandibular spaces.

Clinical Presentation. It presents with characteristic edema of the retromandibular and parotid region, difficulty in swallowing and pain mainly during chewing, which radiates to the ear and temporal

region. In certain cases there is redness of the skin and subcutaneous fluctuation. Also, a purulent exudate may be noted from the papilla of the parotid duct after pressure is applied.

Treatment. Depending on the margins of the edema, therapy entails a broad incision posterior to the angle of the mandible, taking particular care not to injure the respective branch of the facial nerve. Drainage of pus is achieved after blunt dissection using a hemostat to explore the purulent collection.

Knowledge level control:

1. Anatomical and physiological peculiarities of the MFA in children which lead to the development of abscesses and phlegmons.
2. General clinic characteristic of abscesses and phlegmons.
3. Immunologic characteristic of the child's organism.
4. The ways of the infection spreading into the soft tissues of MFA in children.
5. Classification of abscesses and phlegmons.
6. Emergent surgical treatment.
7. Rehabilitation of the patients with abscesses and phlegmons of MFA.

Tests

1. Parents of a 10-year-old girl complain about the presence of facial deformation, painful infiltration, bright hyperemic skin of the cheek. Child restricts mouth opening. The diagnosis - abscess of the buccal area. What are the most probable causes of this abscess?

- A. Postoperative suppuration of hematoma, abscess form of furuncles
- B. Maxillary premolars
- C. Mandibular molars
- D. Alveolitis
- E. Inadequate analgesia.

2. A 9-year-old boy complains about the presence of deformation of the cheek. OBJECTIVELY: there is limited painful infiltrate deep in the cheeks, the skin soldered to infiltrate, brightly hyperemic, difficult taken in the fold. In the center of the infiltration the fluctuation is observed. Mouth opening is somewhat limited and due to pain and tissue infiltration. The mucous membrane of the cheeks hyperemic. The 26 teeth is changed in color, coronal part of the tooth is completely destroyed. Define the diagnosis?

- A. Abscess of buccal area
- B. Abscess parotid-masticatory area
- C. Abscess sublingual space
- D. Abscess retrobulbar space
- E. Phlegmon buccal area.

3. An 11-year-old girl complains of pain, swelling of tissue in the parotid-masticatory area and difficulty mouth opening, headache. Objectively: facial asymmetry due to swelling of tissues in the. Palpation of the parotid-masticatory area revealed dense painful infiltrate and tense skin over it. Fluctuation is observed. Mouth opening is somewhat limited, painful. The mucous membrane of the cheek is swollen with imprints of teeth. The 36 tooth is changed in color, painful to percussion, crown of the tooth is completely destroyed. Define the diagnosis?.

- A. Abscess of the parotid-masticatory area
- B. Pterigomandibular abscess
- C. Infratemporal fossa abscess
- D. Abscess of infraorbital space
- E. Abscess retrobulbar space.

4. A 12-year-old boy complains of pain in the eye, which is growing, bulging eyes, headaches, blurred vision. OBJECTIVELY: Inflammatory swelling of eyelids, conjunctival mucosa is hyperemic and edematous. The diagnosis is abscess of the retrobulbar space. What are the possible complications of this abscess

- A. Spreading of infection to the brain Meninges, sinuses, brain
- B. Sinusitis
- C. Constant headache
- D. Spreading of infection to the brain
- E. Spreading of infection to the brain sinus.

5. A 10-year-old boy has an acute odontogenic osteomyelitis from the 36 tooth which is complicated with pterigomandibular abscess . Which anaesthesia is advisable to conduct for surgical manipulation in this case?

- A. General anesthesia
- B. Central anesthesia флэек Bershe-Dubov
- C. Infiltration anesthesia
- D. Tuberal and palate and anesthesia
- E. Torus anesthesia.

PRACTICAL LESSON № 5

Theme.Odontogenic inflammatory jaw cysts of primary and permanent teeth. Clinic, diagnostics, differential diagnostics.Methods of treatment.

Aim of the lesson. To familiarize students with peculiarities of the diagnosis, clinical course and treatment modalities of the odontogenic inflammatory cysts of the jaws in children.

Control of the initial level of knowledge:

1. Anatomical and physiological characteristics of the structure of milk and permanent teeth, jaw bones in children that contribute to the emergence and development of inflammatory cysts of the jaws in children.
2. Significance of chronic foci of infection in the jaw-facial area in the origin and development inflammatory cysts of the jaws.
3. The value of reactivity in child development and progression of inflammatory cysts of the jaws.
4. The importance of early diagnosis and proper treatment of inflammatory cysts of the jaws.
5. Define the terms "cyst"and its morphology.

Content of the lesson:

Cysts of the Jawsbelong to tumor-like neoplasm.

A cyst is a pathological cavity with fluid, semi-fluid or gaseous contents, which is not created by accumulation of pus. Jaw cysts predominantly arise from odontogenic epithelium and grow by involving epithelial proliferation, bone resorption by prostaglandins, and variations in intracystic osmotic pressure.

Most jaw cysts behave similarly—they grow slowly and expansively. They differ mainly in relationship to teeth and radiographic features. They form sharply-defined radiolucencies with smooth borders and are frequently a chance radiographic finding.

Classification of cysts of the jaws:

1. Odontogenic cysts of the inflammatory origin (55% of all cysts – epithelial rests of Malassez):

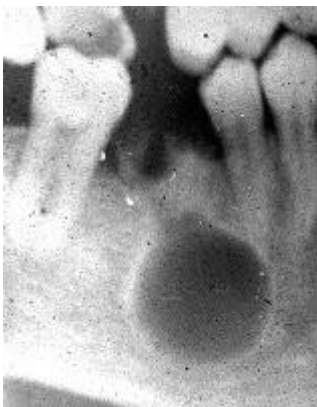- radicular (periapical)
 - radicular tooth-containing
 - residual (cyst remains following removal of non-vital tooth).
2. Odontogenic cysts of the non-inflammatory origin:
- follicular (dentigerous, impacted tooth)- arise in bone around crown of unerupted tooth
 - eruption (primordial) cyst (often burst spontaneously, rarely require excision).
3. Non-odontogenic cysts-defect of the development:
- fissural (incisive canal, nasopalatine duct cysts, globulomaxillary, nasolabial)
 - traumatic (solitary, haemorrhagic, without membranous).

RADICULAR CYST (Periapical cyst, apical cyst)

The most frequent cyst of the teeth bearing areas is the radicular, also called periapical or apical cyst. Around 60% of all jaw cysts are radicular or residual cysts. Radicular cysts can occur in the periapical area of any teeth, at any age. This cyst is classified as inflammatory, because in the majority of cases it is a consequence to pulpal necrosis following caries, with an associated periapical inflammatory response. The first line of defense to pulpal necrosis in the periapical area is the formation of a granuloma. A granuloma is a highly vascularized tissue containing a profuse infiltrate of immunological competent cells i.e., lymphocytes, macrophages, plasma cells, etc.

The epithelial rests of Malassez are remnants from the root sheath of Hertwig which are found in large numbers within the periapical area of all teeth. These epithelial cells derive from the ectoderm that gave rise to the tooth germ and they preserve their metaplastic embryonal potential. Therefore, they can differentiate into any type of epithelium, under the proper stimuli. These rests play a central role in the formation of radicular cysts. In the midst of the rich vascular area provided by the periapical granuloma, the rests of Malassez proliferate and eventually form a large tridimensional mass of cells. With continuous growth the inner cells of the mass are deprived of nourishment and they undergo necrosis by liquefaction. This conduces to the formation of a cavity which is located in the center of the granuloma, giving rise to a radicular cyst.

The radiological image of the radicular cyst is a peri- or para-apical, round or oval radiolucency of variable size which is generally well delineated and most likely with a marked radiopaque rim. Other lesions, such as: granulomas, neoplasms of various origin and some diseases of bone can also present a similar radiolucent periapical appearance. Therefore, a periapical radiolucency can not be automatically assumed to be a cyst. Several studies have indicated that it is not possible to rely on the radiographic size of a periapical radiolucency to establish the diagnosis of either cyst or granuloma unless the lesion is larger than 2 cm in diameter. Rarely radicular cysts will induce resorption of the root of the affected tooth.



This is a typical appearance of apical radiolucency. Note the well delineated cavity with a marked radiopaque rim. The biopsy proved this to be a radicular cyst. Note the radicular rest corresponding to the roots of a first mandibular molar.

The diagnosis of radicular cyst or granuloma can only be made after histologic examination of the lesion. The size of these radiolucencies is not indicative of their diagnosis, either lesion can present great variation in its size, reflected by the amount of bone resorption as a result of pressure applied by the growing lesion into the surrounding bone.

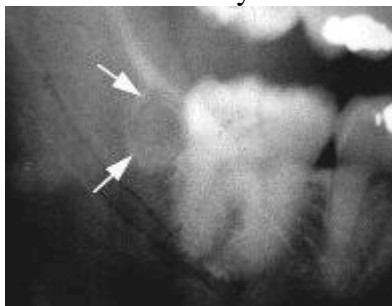
Radicular cysts are generally asymptomatic unless they are secondarily infected, in which case they will be accompanied by pain and the other signs and symptoms of inflammatory-infectious processes. Radicular cysts may vary in size from 1/2 to 2 centimeters or more in diameter. When a cyst reaches a large size it may produce intraoral or facial asymmetry and even paresthesia due to compression of nerves. Occasionally a large cyst may erode the bone cortical plate or invade the maxillary sinus or the nasal fossae. Around 60% of all radicular cysts occur in the maxilla and rarely extend palatally. Patients with extremely large radicular cysts may be at risk of accidental secondary fractures of bone.

RESIDUAL CYST

A residual cyst arises as a consequence of an improper surgical elimination of a radicular cyst. Its clinical and histological characteristics are identical to those of a radicular cyst. Radiologically it will be seen as a radiolucency of variable size at the site of a previous tooth extraction. Treatment consists of endodontic therapy or extraction of the associated tooth with curettage of the cyst.

PARADENTAL CYST

The paradental cyst is an inflammatory cyst which develops on the lateral surface of a tooth root. Histologically the paradental cyst can not be differentiated from a radicular cyst. Some authors refer to this cyst as an inflammatory periodontal cyst or collateral cyst. This cyst is of rare occurrence and must be radiographically differentiated from the lateral periodontal cyst. It is treated by surgical ablation and does not have a tendency to recur.



The arrows point to the periphery of a paradental cyst associated to the distal wall of a 3rd mandibular molar. This cyst is also considered inflammatory in etiology.

DENTIGEROUS (follicular) CYST

Dentigerous cyst is an odontogenic cyst of developmental origin - associated with the crown of an unerupted (or partially erupted) tooth. Since the dentigerous cyst develops from follicular epithelium it has more potential for growth, differentiation and degeneration than a radicular cyst. Due to the tendency for dentigerous cysts to expand rapidly, they may cause pathological fractures of jaw bones. The usual radiographic appearance is that of a well-demarcated radiolucent lesion attached at an acute angle to the cervical area of an unerupted tooth. The border of the lesion may be radiopaque. The radiographic differentiation between a dentigerous cyst and a normal dental follicle is based merely on size.

Surgical treatment.

There are 2 ways of surgical treatment of odontogenic cysts - cystectomy and cystotomy. Indications for choosing one of these methods depend on the pathogenesis of the disease, the size of the cyst, number of teeth involved in the process.

Cystectomy - is a radical operation with the complete removal of the cyst with the capsule, followed by suturing the wound tightly.

The indications for this operation are:

- * The radicular cyst, which is separated from the genyantrum. Cyst large, located on the upper jaw, in the absence of teeth in its area, while maintaining the bottom wall of the nasal cavity and adjacent to the maxillary sinus, in the absence of inflammation in it
- * The radicular cyst of small size (in the range of 1-2 teeth).
- * If the thickness of the preserved bones is 0.5-1 cm, which prevents the fracture
- * Follicular cyst, when the follicle of the permanent tooth is dead.

Cystotomy - a method of a surgical treatment of cysts, which removed the front wall of the cyst and combine it with the vestibule or the oral cavity proper. This operation is less traumatic, easier tolerated, but has a longer postoperative period.

The indications for this surgery are:

- * Cyst in a projection which includes 3 intact teeth
- * Follicular cysts of the jaw
- *Radicular cyst from the primary tooth (tooth-containing), which has the permanent follicle inside of the cyst
- * Radicular cysts on the upper jaw with the destruction of the bone of the nasal cavity and palatal plate
- * The large radicular cyst in the mandible with a severe thinning of the jaw base.

Knowledge level control:

1. The etiology of inflammatory cysts of the jaws of primary and permanent teeth.
2. The pathogenesis of inflammatory cysts of the jaws of milk and permanent teeth.
3. Pathologic picture of inflammatory cysts of the jaws of milk and permanent teeth.
4. The incidence of inflammatory cysts of the jaws, their localization.
5. Features of the clinical course of inflammatory cysts of the jaws.
6. X-ray study of inflammatory cysts of the jaw and its relevance for differential diagnosis with other diseases of jaw-facial area.
7. What methods of surgical treatment of cysts of the jaws do you know?
8. Stages of cystotomy.
9. Stages of cystectomy.

Tests

1. Parents of a 9-year-old boy appealed to a dentist with complaints of deformation of the mandible on the left. On radiographs of the mandible bone defect with sharp edges 2 - 3 sm containing 44 tooth follicle is observed. Define a diagnosis
 - A. Follicular cyst
 - B. Radicular cyst
 - C. Osteoma
 - D. Osteoblastoma
 - E. Ameloblastoma.

2. A 13-year-old child appealed to a dentist with complaints of discoloration of the 11 tooth. From history we know that 4 years ago the injury of the front section of the upper jaw occurred. OBJECTIVELY: the 11 tooth intact, percussion is painless. ON The X-ray: the bone is thin at the top of the root of tooth 11 with clear oval edges. Your diagnosis:
 - A. Radicular cyst
 - B. Residual cyst
 - C. Radicular tooth containing cyst
 - D. Follicular cyst
 - E. Ameloblastoma.

3. In a 8 year-old boy during the objective intraoral examination dentist revealed absence of the 36 tooth. According to other parents first permanent molars erupted in time. The boy doesn't have any complaints. After the radiographic examination of the mandible homogeneous cysts rounded smooth with clear edges was revealed. The coronal part of the 36 tooth is in cyst. Define the diagnosis
 - A. Follicular cyst of the mandible
 - B. Radicular cyst of mandible
 - C. Residual cyst
 - D. Odontoma from 36 teeth of the mandible

E. Osteoblastoma.

4. A 9 year-old girl during treatment of the 75 tooth the homogeneous rounded thinning of bone was found. There is the temporary tooth roots and permanent tooth in follicle. What diagnosis can be assumed by X-ray?

- A. Radicular cyst from 75 tooth
- B. Follicular cyst from 75 tooth
- C. Residual cyst
- D. Cyst of eruption
- E. Ameloblastoma.

5. A 16-year-old patient complains of the slight swelling in the right lower jaw area. Objectively: there is a slight asymmetry of the face in right lower jaw area. The 45 tooth is absent. The X-ray of the right half of the lower jaw in a lateral projection revealed the cell of bone tissues of oval form (2*3 cm), with clear contours. The reverse crown part of horizontally placed the 45 tooth is localized in the cavity. What is the most credible diagnosis?

- A. Follicle cyst of the lower jaw
- B. Osteoblastoclastoma of the lower jaw
- C. Odontoma of the lower jaw
- D. Adamantinoma of lower jaw
- E. Sarcoma of the lower jaw.

PRACTICAL LESSON № 6

Theme. Acute and chronic, odontogenic and non-odontogenic lymphadenitis of the maxillofacial area. Complications and its prevention.

Aim of the lesson. To familiarize students with peculiarities of the clinical course of the acute and chronic lymphadenitis in children, their treatment.

Control of the initial level of knowledge

1. Anatomical and physiological peculiarities of the lymphatic system in children.
2. The ways of the infection spreading into the regional lymphatic nodes.

Content of the lesson

Lymphadenopathy is a term meaning "disease of the lymph nodes." It is, however, almost synonymously used with "swollen/enlarged lymph nodes". It could be due to infection, autoimmune disease or malignancy.

Inflammation of a lymph node is called lymphadenitis. In practice, the distinction between lymphadenopathy and lymphadenitis is rarely made. Inflammation of lymph channels is called lymphangitis.

The majority of enlarged lymph nodes are the result of an acute or chronic response to an infectious organism (lymphadenitis), but they can also indicate the growth of a metastatic tumor or a primary malignant neoplasm (lymphoma). These infections and malignancies may continue to spread by way of the lymphatic system.

The lymph nodes are bean-shaped organs found in clusters along lymph channels of the body. They have two functions- to remove toxic products from lymph and to prevent their entry into systemic circulation and the production of lymphocytes.

In general, lymph nodes must be larger than 1 cm in diameter to be palpable. Nodes that become palpable due to an acute inflammatory condition tend to be tender, soft, enlarged, and freely movable. They may eventually return to their original size or they may stay enlarged as a result of scar tissue. On the other hand, those lymph nodes that become palpable due to malignant diseases are often fixed surrounding tissues, nontender, hard, and involve multiple nodes.

Despite the frequent and wide communications between smaller and larger lymph vessels, the lymph of any specific region is carried to certain well-defined lymph nodes. Lymph drainage from the superficial tissues of the head and neck generally travels first to groups of superficially placed lymph nodes before passing to the deep cervical lymph nodes. Lymph nodes that received the lymph of a definite region before it has passed through other lymph nodes are called regional lymph nodes. They are the first sites at which pathologic processes will manifest themselves if those processes spread from their primary location via lymph channels. In turn, regional nodes drain into central (or secondary) nodes. Secondary nodes may drain into tertiary ones.

There are few groups of the head and neck lymph nodes:

- Calvarium region (occipital, mastoideus superficial and deep, auricular);
- Facial (buccal, submandibular, epimandibular, submental);
- Cervical (superficial and deep)

Classification of lymphadenitis

By topography and anatomical principles:

- By deepness of localization- superficial and deep
- By localization- (occipital, mastoideus, submandibular, epimandibular etc.)

By way of invasion:

- Odontogenic
- Nonodontogenic- as a result of respiratory and viral infection, sepsis, specific infection (tuberculosis, syphilis, actinomycosis, HIV- infection), metastasis

By the acuteness of process:

- Acute – serous and purulent
- Chronic – hyperplastic, purulent, exacerbated chronic.

Acute serous odontogenic lymphadenitis

Complaints: appearance movable, painful “ball” during the palpation in the certain area. The child would note that it was tooth ache before of the lymph node enlargement.

Clinical course: General condition without significant changes: minimal rising of the body temperature, insignificant intoxication. During examination: spherical lump which is painful during palpation. Mobility of the lump could be limited and it would be the sign of spreading of the process to the surrounding tissues. The skin above the lymph node is without changes. There is no enlargement of the lymph node from the other site. During oral cavity examination the causative tooth with positive percussion can be revealed. In most cases the diagnosis of periapical inflammation is easily determined.

Acute purulent odontogenic lymphadenitis.

Acute purulent lymphadenitis is the next step of the serous form without treatment. If it is no treatment of the serous form during 5-7 days –the serous inflammation goes to purulent form.

Complaints of: enlarged node with pulsative pain, significant increasing of the body temperature, loss of appetite, behaviour changes.

Clinical course: Assymetry of the face due to swelling of the certain region. Swollen and hyperaemic skin. Painful, enlarged lymph node without clear borders during palpation. Fluctuation is not always present because of tight capsule of the lymph node. Opening of the mouth is not limited, the causative tooth can be easily found. In the blood: left shift of the leucocytes.

Chronic odontogenic lymphadenitis is rarely observed in kids.

Complaints of the presence of lump for the long time without inconvenience. During oral cavity examination the causative tooth with pain in anamnesis is often revealed.

Clinical course: Slight facial asymmetry in the area of lesion with unchanged skin over it. Slightly painful, solid, round or oval lymph node with restricted mobility is revealed by palpation with

fluctuation in the center of it. Mouth opening is not limited. The causative tooth is changed in color or could be absent.

Treatment.

The main principle of the treatment of lymphadenitis is elimination of the etiology factor that leads to disease appearance.

Conservative treatment: - compress of 5% sol. of Dimexid with anti-inflammatory means in it (Hydrocortisone, Analgin, Dimedrol).

Physiotherapeutic treatment (during first 2-3 days after the onset): phonophoresis of Hydrocortisone, electrophoresis of Dimexid with antibiotics and Dimedrol, Laser.

The main method of purulent forms treatment of lymphadenitis is the surgical one which is performed in the hospital under the general anesthesia.

Knowledge level control

1. Anatomical and physiological peculiarities of the jaw-facial area in children which influence on the development of the acute and chronic lymphadenitis.
2. Immunological characteristic of the child's organism.
3. The ways of infection spreading into the regional lymph nodes.
4. Classification of the lymphadenitis in children.
5. General clinical characteristic of the acute and chronic lymphadenitis.
6. Surgical and medicamentous methods of treatment of the different forms of lymphadenitis.

Tests

1. Child 7 years old complains of pain and swelling in the left submandibular area. Swelling in this area appeared 2 days ago. OBJECTIVE: asymmetrical face due to soft tissue swelling in the left submandibular area. Palpation revealed the formation of spherical shape, movable, not soldered to the skin, painful. 74 teeth changed in color, it is painful percussion. Put the right diagnosis.
 - A. Odontogenic acute serous lymphadenitis left submandibular area
 - B. Non-odontogenic acute suppurative lymphadenitis left submandibular area
 - C. Non-odontogenic acute serous lymphadenitis right submandibular area
 - D. Non-odontogenic acute serous lymphadenitis left submandibular area
 - E. Odontogenic acute suppurative lymphadenitis left submandibular area.
2. A 14-year-old child arrived to a clinic with complaints on asymmetric face with a thick infiltrate in the submandibular area. Objectively: the transitional fold in the projection of the 37 tooth root is a cord. The diagnosis: chronic odontogenic hyperplastic lymphadenitis of the left submandibular area of the 37 tooth. Select the optimal therapeutic treatment?
 - A. Removal of the 37 teeth and surgical removal of the lymph node with subsequent pathological study
 - B. Endodontic treatment of the 37 tooth and surgical removal of the hyperplastic lymph node
 - C. Endodontic treatment of the 37 teeth and removal of lymph node parenchyma
 - D. Surgical removal of lymph node
 - E. Extraction of the 37 teeth.
3. Boy 11 years / The parents of a 3-year-old boy appealed to a dental surgeon with complaints of the presence of tumor in a superciliary area. Objectively: in a right superciliary area there is a 2 cm tumor of soft-elastic consistency, round in shape. A skin above a slight swelling is neither changed nor soldered with it. The puncture revealed a mass of white color. What is the most reliable diagnosis?
 - A. Dermoid cyst of the right superciliary area
 - B. Epidermoid cyst of the right superciliar area
 - C. Lymphangioma of the right superciliar area
 - D. Hemangioma of the right superciliar area
 - E. Cerebral hernia.

4. A girl of 2 years old has temperature 38.5, a slight swelling under a jaw from the right side. She is ill for 5 days, when a cold, cough, small mobile ball appeared under a lower jaw on the right side. Objectively; the common state of the child of middle weight. Face asymmetric because of a slight swelling in the right under mandibular area. The skin is blushing, brilliant, here is a poured edema in the right under mandibular area, that spreads to the overhead department of a neck from the right side, tender painful, dense, the skin does not undertake in a fold. The teeth are healthy. What is the most reliable diagnosis?

- A. Acute nonodontogenic submandibular lymphadenitis
- B. Acute festering periostitis of the lower jaw on the right
- C. Chronic osteomyelitis of the lower jaw on the right
- D. Adenophlegmon of the right under the mandibular
- E. Acute sialadenitis of the right undermandibular salivary gland.

5. Parents of 9-year-old boy complained of the presence of long-existing "balls" in the submaxillary area. From the history the doctor discovered that the "ball" was a month ago, along with the appearance of pain in tooth 75. Tooth not treated. Parents point to several aggravations, are manifested slight fever, increasing pain and its node against acute process in the tooth. OBJECTIVE: node tight, limited, mobile, oval shape, center revealed fluctuations. Install the diagnosis

- A. Odontogenic acute purulent lymphadenitis left submandibular area
- B. Exacerbation of chronic odontogenic lymphadenitis
- C. a lymphogranulomatosis
- D. Neodontogenic acute purulent lymphadenitis left submandibular area
- E. Neodontogenic acute purulent lymphadenitis left submandibular area

- A. Exacerbation of chronic odontogenic lymphadenitis
- B. Lymphogranulomatosis
- C. Nonodontogenic acute purulent lymphadenitis of the left submandibular area
- D. Nonodontogenic acute purulent lymphadenitis of the right mandibular area
- E. There is no correct answer.

PRACTICAL LESSON № 7

Theme. Acute diseases of the salivary glands in children: epidemic parotitis, non-epidemic parotitis, calculous and non-calculous submaxillitis. Chronic diseases of the salivary glands in children: parenchymal and interstitial submaxillitis. Clinic, diagnosis, treatment and prevention of diseases of the salivary glands in children.

Aim of the lesson. To familiarize students with peculiarities of the clinical course of the acute and chronic sialadenitis in children, their treatment.

Control of the initial level of knowledge:

1. Anatomical and physiological peculiarities of salivary glands in children.
2. Chemical composition of the saliva.
3. Methods of the salivary glands examination: anamnesis, bimanual palpation of the glands and lymph nodes, roentgenography and sialography, ultrasound examination.
4. Classification of the salivary glands diseases.

Content of the lesson:

Saliva is produced by the three pairs of major salivary glands - the parotid, submandibular and sublingual glands as well as the many hundreds of small salivary glands scattered throughout the

buccal and pharyngeal mucosa. The majority of surgical pathology affects the parotid or submandibular gland, with the sublingual and minor salivary glands being less frequently affected.

Anatomy

Parotid gland

The parotid gland is the largest of the salivary glands. It lies just in front of the ear extending from the zygomatic arch downwards to between the angle of the mandible and the mastoid process. This inferior portion is also known as the tail of the parotid gland. The anterior border corresponds approximately to the ascending ramus of the mandible. It is important to appreciate that the tail of the parotid gland extends into the neck and that lesions in this area can affect the parotid gland and are sometimes mistaken for lymph nodes in the neck. Swellings in this area should be assumed to be arising from the parotid until proven otherwise. The facial nerve is intimately associated with the parotid gland and runs through the gland, dividing it into a superficial lobe, which arises lateral to the facial nerve, and a deep lobe, which arises deep to the facial nerve. This is an artificial division and no true anatomical plane exists between the superficial and the deep lobe. A normal parotid gland consists of 80% superficial lobe and 20% deep lobe. The facial nerve enters the parotid gland from the stylomastoid foramen and, shortly after entry, divides into an upper and lower division. The upper division gives off a temporal branch that supplies the muscles of the forehead and eye, a zygomatic branch that supplies the muscles of the eye, and occasionally a buccal branch that supplies the muscles of the nostril and upper lip. The lower division gives off a mandibular branch that supplies the muscles of the lower lip and a cervical branch that supplies platysma in the neck. The lower division often also gives off the buccal branch. The facial nerve controls the muscles of facial expression. The parotid gland is drained by the parotid duct, which opens into the mouth opposite the second upper molar tooth.

Submandibular gland

The submandibular gland lies in the submandibular triangle bordered anteriorly by the digastric muscle, posteriorly by the stylomandibular ligament and superiorly by the mandible. This gland also has a superficial and deep part, the superficial being the largest. The superficial lobe lies superficial to the mylohyoid muscle, whereas the deep lobe lies deep to the mylohyoid muscle and is drained by a duct that drains forwards and upwards to open close to the frenulum in the floor of the mouth. Three nerves are closely linked to the submandibular gland - the marginal mandibular branch of the facial nerve, the lingual nerve and the hypoglossal nerve. As mentioned above, the marginal mandibular nerve supplies the muscles of the lower lip and damage to this nerve will leave the patient with deformity. The lingual nerve supplies sensation to the anterior two-thirds of the tongue whereas the hypoglossal nerve supplies motor function to the tongue muscles.

Sublingual gland

The sublingual gland is the smallest of the major glands and lies beneath the mucosa of the floor of the mouth near the midline. It drains into the mouth by small ducts, as well as by ducts that open directly into the submandibular gland duct. It is closely associated with the lingual nerve.

Classification of the salivary gland inflammation diseases:

1. By the etiology: - viral, - bacterial, - traumatic, - calculous
2. By the spreading: - acute (serous, purulent, purulent necrotic),
- chronic (parenchymatous, interstitial),
- chronic recurrent.
3. By the localization: - parotitis, - submaxillitis.
4. By the concret content: -non-calculous, calculous with the localization of the stone in :
- the frontal region of the duct,
- the medium region of the duct,
- the back region of the duct,
-the gland.

Most surgical pathology of the salivary gland presents as a swelling in the associated gland and it is helpful clinically to characterise the swelling as one that affects the whole of the gland or as a discrete swelling that affects only part of the gland. Most discrete swellings are caused by a tumour,

whereas swellings affecting the whole of the gland are usually caused by sialolithiasis, sialadenitis or sialadenosis. There is obviously some overlap in this classification but it is helpful in the clinical context.

Sialadenitis is inflammation of the salivary glands, most commonly the parotid, and can be categorised into acute and chronic types.

Mumps (epidemic parotitis) is a viral disease, caused by the Paramixovirus. Before the development of vaccination and the introduction of a vaccine, it was a common childhood disease worldwide. Painful swelling of the salivary glands (classically the parotid gland) is the most typical presentation. Painful testicular swelling (orchitis) and rash may also occur. The symptoms are generally not severe in children. In teenage males and men, complications such as infertility or subfertility are more common, although still rare in absolute terms. The disease is generally self-limited, running its course before receding, with no specific treatment apart from controlling the symptoms with pain medication.

The more common symptoms of mumps are:

- Parotid inflammation (or parotitis) in 60–70% of infections and 95% of patients with symptoms. Parotitis causes swelling and local pain, particularly when chewing. It can occur on one side (unilateral) but is more common on both sides (bilateral) in about 90% of cases.
- Fever
- Headache
- Pain behind the ear during palpation (Filatova's symptom)
- Characteristic painful dots: in front of the tragus, top of the processus mastoideus, incisura of the mandible, angle of the lower jaw (Hatchcock's symptom)
- Hyperemic orifice of the duct (Tresilian – Mourson's symptom)
- Orchitis, referring to painful inflammation of the testicle. Males past puberty who develop mumps have a 30 percent risk of orchitis development.
- Other symptoms of mumps can include dry mouth, sore throat and/or ears and occasionally in more serious cases, loss of voice. In addition, up to 20% of persons infected with the mumps virus do not show symptoms, so it is possible to be infected and spread the virus without knowing it.

Fever and headache are prodromal symptoms of mumps, together with malaise and anorexia.

Cause. Mumps is a contagious disease that is spread from person to person through contact with respiratory secretions such as saliva from an infected person. When an infected person coughs or sneezes, the droplets aerosolize and can enter the eyes, nose, or mouth of another person. Mumps can also be spread by sharing food and drinks. The virus can also survive on surfaces and then be spread after contact in a similar manner. A person infected with mumps is contagious from approximately 6 days before the onset of symptoms until about 9 days after symptoms start. The incubation period (time until symptoms begin) can be from 14–25 days but is more typically 16–18 days.

Diagnosis. A physical examination confirms the presence of the swollen glands. Usually the disease is diagnosed on clinical grounds and no confirmatory laboratory testing is needed. If there is uncertainty about the diagnosis, a test of saliva or blood may be carried out; a newer diagnostic confirmation, using real-time nested polymerase chain reaction (PCR) technology, has also been developed. An estimated 20%-30% of cases are asymptomatic. As with any inflammation of the salivary glands, serum amylase is often elevated.

Prevention. The most common preventative measure against mumps is immunization with a mumps vaccine. The vaccine may be given separately or as part of the MMR immunization vaccine which also protects against measles and rubella. The WHO (World Health Organization) recommends the use of mumps vaccines in all countries with well-functioning childhood vaccination programmes.

Treatment. There is no specific treatment for mumps. Symptoms may be relieved by the application of intermittent ice or heat to the affected neck/testicular area and by acetaminophen/paracetamol (Tylenol) for pain relief. Aspirin is not used due to a hypothetical link with Reye's syndrome. Warm salt water gargles, soft foods, and extra fluids may also help relieve

symptoms. Patients are advised to avoid fruit juice or any acidic foods, since these stimulate the salivary glands, which can be painful.

Prognosis. Death is very unusual. The disease is self-limiting, and general outcome is good, even if other organs are involved. Known complications of mumps include:

Infection of other organ systems

Mumps viral infections in adolescent and adult males carry an up to 30% risk that the testes may become infected (orchitis or epididymitis), which can be quite painful; about half of these infections result in testicular atrophy, and in rare cases sterility can follow.

Spontaneous abortion in about 27% of cases during the first trimester of pregnancy.

Mild forms of meningitis in up to 10% of cases (40% of cases occur without parotid swelling)
Oophoritis (inflammation of ovaries) in about 5% of adolescent and adult females, but fertility is rarely affected.

Pancreatitis in about 4% of cases, manifesting as abdominal pain and vomiting.

Encephalitis (very rare, and fatal in about 1% of the cases when it occurs).

Profound (91 dB or more) but rare sensorineural hearing loss, uni- or bilateral. Acute unilateral deafness occurs in about 0.005% of cases.

After the illness, life-long immunity to mumps generally occurs; reinfection is possible but tends to be mild and atypical.

Acute Sialadenitis

Acute sialadenitis may be bacterial or viral in nature. Bacterial infection usually presents with a sudden sense of swelling of the affected gland and there may be redness of the overlying skin. Pus is often seen exuding from the salivary gland duct into the mouth and the patient is unwell. Most acute bacterial infection is related to a reduction in the flow of saliva but the quality of saliva is without changes in the serous form and in the purulent stage the saliva is secreted with the pus. Regional lymphadenitis is often present.

In children an acute bacterial sialadenitis is mostly observed in the age of 7-12 years. There is often an association with poor oral hygiene. It used to be a common postoperative finding but now, with the use of antibiotics and better fluid management and postoperative oral toilet, it has become an uncommon disease.

There are two forms of the disease: - serous and purulent.

Diagnosis is setted due to complaints and clinical sings (enlarged, painful salivary gland, hyperemic and shiny skin over it; saliva with pus is secreted during massage of the gland).

Treatment is usually with antibiotics (macrolids, penicillin-row), antihistamins, immunostimulating drugs and correction of the underlying disease processes if present. Sialogogues (e.g. citrus-flavoured sweets) are often given to encourage the flow of saliva. With the presence of the purulent secretion the proteolytic enzymes are prescribed. If an abscess develops it may need draining externally. Care must be taken not to damage the facial nerve when the parotid gland is affected.

Chronic sialadenitis has several causes and usually presents with persistent inflammation and enlargement of the affected gland. Mainly it is observed four times often then the acute stage and in children of 8-15 years old.

Chronic recurrent sialadenitis. This presents mainly as a unilateral or alternating swelling of the parotid gland, which can be painful. Also the general condition of the child is disturbed. It is mainly a disease of children and the saliva can be very milky or purulent. Few reccurences are revealed due to anamnesis. Clinical picture is mostly the same as with acute bacterial sialadenitis but inflammation is less marked. Attacks occur at variable intervals and in between attacks the child is totally symptom free. The gland is solid and hilled in the remission stage and can enlarge after reccurency. The underlying cause is not known but it is thought that duct ectasia may be a predisposing factor.

Diagnosis is again made from the history and sialography can be considered. Duct ectasia supports the diagnosis when seen on sialography.

Treatment is symptomatic as the underlying cause is not fully understood. It often involves antibiotics, antihistamins, vit. B, C and analgesia and sialogogues are often given. Most cases in

childhood disappear after puberty. If the attacks continue, ligation of the parotid duct or a tympanic neuroectomy can be recommended. It is very occasionally necessary to perform a parotidectomy.

For prevention of recurrences the massage of the gland three times a day (3-5 min.) is recommended. Ultrasound and laser therapy facilitate of the improvement of the microcirculation of the gland.

Sialolithiasis

Sialolithiasis, or salivary gland stone disease, is caused by the presence of stones either within the gland itself or in the duct that is draining the gland, symptoms being more common when the stones are found in the ducts.

The main complaint is painful enlargement of the gland during eating (especially due to sour and salted meal), but later – slow decreasing of its size.

Clinical features: asymmetry of the submandibular area, free mouth opening, mucosa around the duct is hyperemic, saliva is transparent or with the pus. If the stone is located inside the gland, the gland becomes enlarged with smooth surface. The stone in the duct can be revealed during bimanual palpation in the direction from the gland to the duct. As the result of the sialolithiasis the significant reformation of the gland tissues is happen. X-ray examination is helpful for the setting of the diagnosis. But it is important to take into consideration that stones are not always clearly visible during X-ray in children.

Stones in the anterior part of the submandibular duct (submandibular gland is the most characternal gland for stone appearance – because of its S- shaped duct anatomy) can be removed via the mouth by opening (and marsupialising) the duct but if the stone is further back in the duct, or in the submandibular gland itself, then it is safer to remove the gland externally by a neck incision to avoid damage to the lingual nerve. Recurrent parotid duct stones are rare and if they cannot be removed through the mouth and are considered very troublesome then they require a parotidectomy, but this is very unusual. Dilatation of the parotid duct has been tried for parotid duct stones, especially when they are associated with a stricture in the parotid duct, and this is worth trying as it is a lot less invasive and has lower morbidity than a parotidectomy, but its effectiveness is doubtful.

Knowledge level control:

1. Etiology of mumps.
2. Clinical manifestation and complications of mumps.
3. Differential diagnosis of mumps.
4. Treatment of mumps.
5. Prognosis.
6. The etiology of acute bacterial sialoadenitis.
7. Clinical features of acute bacterial sialoadenitis.
8. Differential diagnosis of acute bacterial sialoadenitis.
9. Pseudoparotitis Hertsenberha.
10. Treatment of acute bacterial sialoadenitu.
11. Clinical peculiarities of the chronic parenchymatous parotitis.
12. Sialography as the method of the diagnostic of parenchymatous parotitis in different time periods of the disease.
13. Differential diagnostics of the salivary glands diseases.
14. Methods of treatment of the chronic parenchymatous parotitis.
15. Prognosis.
16. Clinical features adn diagnostics of the sialolithiasis.
17. Roentgenography and sialography in the diagnostic of sialolithiasis.
18. Policy of treatment with exacerbation of sialolithiasis.
19. Indications to the surgical treatment.
20. Clinical features, diagnostics and differential diagnostics of the mumps.
21. Treatment peculiarities and prognosis of the mumps.

Tests

1. The 15 years old patient, complains of headache, dry mouth, body temperature 38,4 ° C, enlarged parotid area. Objective: facial asymmetry due to painful swelling of parotid-masticatory areas. Lobe upraised ears. Skin pale. With duct parotid salivary gland saliva hardly stands out. Mursona symptom is noted. Put the most likely diagnosis.

- A. Parotitis
- B. Pseudoparotyt Hertsenberh
- C. Exacerbation of chronic parotitis
- D. The disease Mikulich
- E. Acute serous parotitis.

2. The 7 years-old boy observed an symmetrical swelling of the parotid areas, characterized by pain on palpation in the region of mastoid process and tragus ear. Characteristic dryness of the oral mucosa. Hiposalivatsiya. Diagnosed mumps, mild severity. Select a medical tactic in the specified severity?

- A. Ambulatory treatment of child insulation
- B. Ambulatory treatment without isolation of the child
- C. A child may attend child care centers
- D. Hospitalization in the Infectious Diseases Hospital
- E. Hospitalization in Children's Department of Oral and Maxillofacial Surgery.

3. Parents of a 4 years-old child complain of swelling of the soft tissue in both parotid-masticatory areas, increased body temperature to 38.2 C. OBJECTIVE: both salivary glands increase, palpation soft and tender. The skin is tense, pale, shiny. Put the diagnosis.

- A. parotitis
- B. Bacterial parotitis
- C. Chronic parotitis
- D. calculouse sialoadenitis
- E. Pseudoparoty Hertsenberha.

4. A 11 years-old child complains of pain and swelling in the parotid-masticatory area of the right side, fever up to 38,2 ° C. Ill about 5 days. OBJECTIVE: In the parotid-masticatory area right palpation is painful tight formation of 3,5 h5sm. Skin is not changed in color. From the mouth of the salivary gland duct thing stands out clear secret. What is the most likely diagnosis?

- A. False parotitis Hertsenberha
- B. Mixed tumor of the parotid gland
- C. Exacerbation of chronic parenchymatous parotitis
- D. parotitis
- E. abscess of cheek.

5. A 16year-old patient turned to the doctor with complaints about the presence of swelling in the right parotid-masticatory area, a feeling of heaviness in the area of gland salty discharge from the ducts. OBJECTIVE: swelling in some parts of the existing sealing painless. The mouth opens easily, mucous cheeks pink and moist. With duct salivatewith admixtures of mucus. Quantity of diminished. What is the most likely diagnosis?

- A. Chronic sialoadenit
- B. Acute sialodohit
- C. The disease Mikulich
- D. parotitis
- E. Sjogren's Syndrome Hutnera.

PRACTICAL LESSON № 8

Theme. Acute and chronic inflammatory diseases of temporomandibular joint (TMJ) in children. Secondary osteoarthritis, ankylosis. Causes of development, diagnosis, differential diagnosis, clinical course. Principles and stages of surgical and medicamentous treatment. Rehabilitation of such patients.

Aim of the lesson. To familiarize students with peculiarities of the clinical course of the acute chronic inflammatory diseases of the TMJ in children

Control of the initial level of knowledge

1. Definition of arthritis.
2. Reasons of the TMJ diseases.
3. Principles of the differential diagnostics of the TMJ diseases.
4. Pathogenesis of the junior functional disturbances of the TMJ.
5. Dispensary of the children with TMJ diseases.
6. To study the anatomical and physiological and functional features of the temporomandibular joint in the age aspect.
7. The functions of the temporomandibular joint.
8. Pathophysiology of the inflammatory process.
9. Examination of patients with TMJ disorders.

Content of the lesson:

The temporomandibular joint (TMJ) is composed of the temporal bone and the mandible, as well as a specialized dense fibrous structure, the articular disk, several ligaments, and numerous associated muscles. The TMJ is a compound joint that can be classified by anatomic type as well as by function. Anatomically the TMJ is a diarthrodial joint, which is a discontinuous articulation of two bones permitting freedom of movement that is dictated by associated muscles and limited by ligaments. Its fibrous connective tissue capsule is well innervated and well vascularized and tightly attached to the bones at the edges of their articulating surfaces. It is also a synovial joint, lined on its inner aspect by a synovial membrane, which secretes synovial fluid. The fluid acts as a joint lubricant and supplies the metabolic and nutritional needs of the nonvascularized internal joint structures. Functionally the TMJ is a compound joint, composed of four articulating surfaces: the articular facets of the temporal bone and of the mandibular condyle and the superior and inferior surfaces of the articular disk. The articular disk divides the joint into two compartments. The lower compartment permits hinge motion or rotation and hence is termed *ginglymoid*. The superior compartment permits sliding (or translatory) movements and is therefore called *arthrodial*. Hence the temporomandibular joint as a whole can be termed *ginglymoarthrodial*.

Classification:

1. By the etiology:
 - innate malformation,
 - acquired: - inflammatory (arthritis)
 - dystrophy (arthrosis, secondary arthrosis deformans)
 - inflammatory- dystrophy (arthritis- arthrosis).
2. By the course:
 - acute, chronic, chronic in the stage of the exacerbation.

3. Ankylosis (fibrous, osseous):

- innate, acquired;
- unilateral, bilateral;
- inflammatory, traumatic.

Infectious arthritis.

Infection of the TMJ may result from direct extension of adjacent infection or hematogenous spread of bloodborne organisms. The child complains of the edema and pain in the parotidomasseterica region with the irradiation into the ear and occiput, limited lower jaw movement, rise of temperature. The pain in the both TMJs appears in the case of rheumatic arthritis, in case of rheumatoid - in one TMJ and knee or shoulder joint.

Clinically the area is inflamed, asymmetry of the face is present due to edema of the soft tissues of parotid area and jaw movement is limited. The mouth opening is painful and limited. The lower jaw is shifted towards the affected side. Local signs of infection associated with evidence of a systemic disease or with an adjacent infection suggest the diagnosis. X-ray results are negative in the early stages but may show bone destruction later. If suppurative arthritis is suspected, the joint is aspirated to confirm the diagnosis and to identify the causative organism. Diagnosis must be made rapidly to prevent permanent joint damage.

Traumatic arthritis

Rarely, acute injury (eg, due to difficult tooth extraction or endotracheal intubation) may lead to arthritis of the TMJ. Pain, tenderness, and limitation of motion occur. Diagnosis is based primarily on history. X-ray results are negative except when intra-articular edema or hemorrhage widens the joint space. Treatment includes NSAIDs, application of heat, a soft diet, and restriction of jaw movement.

Osteoarthritis

The TMJ may be affected, usually in people > 50 yr. Occasionally, patients complain of stiffness, grating, or mild pain. Crepitus results from a hole worn through the disk, causing bone to grate on bone. Joint involvement is generally bilateral. X-rays or CT may show flattening and lipping of the condyle, suggestive of dysfunctional change. Treatment is symptomatic.

Rheumatoid arthritis

The TMJ is affected in > 17% of adults and children with RA, but it is usually among the last joints involved. Pain, swelling, and limited movement are the most common findings. In children, destruction of the condyle results in mandibular growth. Ankylosis may follow. X-rays of the TMJ are usually negative in early stages but later show bone destruction, which may result in an anterior open-bite deformity. The diagnosis is suggested by TMJ inflammation associated with polyarthritis and is confirmed by other findings typical of the disease.

Treatment is similar to that of RA in other joints. In the acute stage, NSAIDs may be given, and jaw function should be restricted. A night guard or splint is often helpful. When symptoms subside, mild jaw exercises help prevent excessive loss of motion. Surgery is necessary if ankylosis develops but should not be done until the condition is quiescent.

Chronic arthritis

Diagnosis of the chronic arthritis is based on:

Typical complaints: "crunch" during mouth opening, morning limitation of movements and moderate pain, which increases during eating, headache, dizziness, ear noise, poor hearing, sometimes – dryness in the mouth/burning of the tongue, long-lasting course of the disease.

Clinical picture: painful joint and tragus palpation, increasing of the pain during pressing of the mental region.

X-ray picture: unequal expansion of the joint space.

Treatment includes antibiotics, proper hydration, pain control, and motion restriction (immobilization with orthodontic apparatus or bandage), physiotherapeutic procedures, anti-inflammatory nonsteroid drugs. Parenteral penicillin G is the drug of choice until a specific bacteriologic diagnosis can be made on the basis of culture and sensitivity testing. Suppurative infections are aspirated or incised. Once the infection is controlled, jaw-opening exercises help prevent scarring and limitation of motion.

Treatment of the chronic arthritis depends from the reasons and changes occurred in the joint. When the functional occlusion is disturbed the main goal of management should be referred to eliminate the etiology factor by the selective reseating of the teeth and occlusion correction.

Secondary degenerative arthritis

This type of arthritis usually develops in people aged 20 to 40 after trauma or in people with persistent myofascial pain syndrome. It is characterized by limited opening of the mouth, unilateral pain during jaw movement, joint tenderness, and crepitus. Diagnosis is based on x-rays, which generally show condylar flattening, lipping, spurring, or erosion. Unilateral joint involvement helps distinguish secondary degenerative arthritis from osteoarthritis.

Treatment is conservative, as it is for myofascial pain syndrome, although arthroplasty or high condylectomy may be necessary. An occlusal splint (mouth guard) usually relieves symptoms. The splint is worn constantly, except during meals, oral hygiene, and appliance cleaning. When symptoms resolve, the length of time that the splint is worn each day is gradually reduced. Intra-articular injection of corticosteroids may relieve symptoms but may harm the joint if repeated often.

Ankylosis – complete or partly limited mobility of the mandible due to changes in the joint. The main reasons are: purulent otitis, trauma of the processus condilaris and fossa condilaris, impact into the mental region, trauma during delivery, osteomyelitis of the processus condilaris.

Unilateral: facial configuration changes, limitation of the mouth opening, impossibility of the food intake. Anamnesis: trauma, otitis, parotitis, infectious diseases.

Clinicaly: facial asymmetry due to decreasing of the size of one half of the jaw, soft buccal tissues have chubby appearance on the affected joint while on the healthy side tissues look flattened. Middle line of the chin and incisal line on the lower jaw are always shifted to the affected joint side. During bimanual palpation of TMJ movements of the head are limited or absent. In the area of the angle of mandible on the affected side the osseous outgrowth (bony spur) is present. Also it can be seen on the X-ray. As the result of the mandible ramus and body shortening dental arches can be deformed as well. On the X-ray: disappearing of the joint space due to fusion of joint surfaces on the affected side, decreasing of the ramus mandibular height, the ramus is wider on the affected side. Processus coronoideus is enlarged by height and looks like pricker.

Bilateral: more often as the result of septic diseases or delivery trauma.

Complaints of deformity of the lower third of the child's face impossibility of the mouth opening, difficulties during feeding, breathing disturbances, snoring.

Clinically: face has bird-like look, open distal bite, mouth opening is restricted, movements of the TMJ heads is not revealed during palpation, roentgenologic – partial or total absence of the joint space, bony tissue which looks like conglomerate; shortening of the rami and body of the mandible, osseous outgrowth on both angles, enlargement of the processus coronoideus from both sides.

Surgical treatment – arthroplasty (osteotomy).

Arthrosis – primary chronic inflammation of the joints of degenerative genesis with primary deformation of the joint cartilage and with following reactive-degenerative processes of the joint surfaces. In children arthrosis is the continuation of the long-lasting and untreated arthritis and doctors have the deal with arthrito-arthrosis.

Complaints of limitation of mouth opening discomfort during jaw movements, slight facial asymmetry.

Clinical signs are divided into joint-related and non-joint-related.

Joint related: movements limitation, rapid fatigability during eating. “Started pain” appears after rest period.

Non-joint related: unilateral microgenia which increases with time, clearly seen on X-ray.

Knowledge level control

1. Anatomy, physiology and function of TMJ.
2. Classification of the TMJ diseases.
3. Methods of examination of patients with TMJ diseases.
4. Acute arthritis, clinical features, differential diagnostics, treatment, prognosis.

5. Chronic arthritis, clinical features, differential diagnostics, treatment, reasons and eventual consequences of disease.
6. Etiology, pathogenesis and pathological picture of primary bone disorders and diseases of TMJ (osteoarthritis, osteoarthritis, ankylosis).
7. Modern principles of treatment of TMJ diseases.
8. Dispensary and treatment of the children with chronic TMJ diseases, preventive measures.
9. Chronic arthritis: symptoms, diagnosis, differential diagnosis, treatment, causes and consequences of the disease.
10. Etiology, pathogenesis and pathology in the picture of primary bone lesions and TMJ diseases (osteoarthritis, osteoarthritis, ankylosis).
11. Diagnosis and differential diagnosis of injuries and diseases of the TMJ.
12. Modern methods and principles of treatment of osteoarthritis and ankylosis.
13. Etiology, pathogenesis, clinical picture and treatment of functional disorders of the bone in children and adolescents, their prevention.
14. Clinical examination and treatment of children with chronic TMJ and their prevention.

Tests

1. A 12-year-old child came for the consultation to the doctor with complaints of the pain and slight swelling in the area of the left TMJ. It is known from the anamnesis, that 2 days ago a child opened his mouth very widely and experienced a severe pain in the area of the joint. Objectively: in the area of the left TMJ there is a slight swelling on palpation; opening of a mouth is limited to some extent. What is the most reliable diagnosis?
 - A. Acute arthritis of the left TMJ
 - B. Arthrosis of the left TMJ
 - C. Juvenile dysfunction of the left TMJ
 - D. Chronic arthritis of the left TMJ
 - E. Anchylosis of the left TMJ.

2. A girl of 14 years old complains of an acute pain in the area of the right temporomandibular joint (TMJ) with irradiation to the ear, headache, difficulties in the mouth opening. Objectively: there is the asymmetry of the face because of the edema in the area of the right TMJ. The skin is blushing, blocked jaw. The palpation of the joint causes an acute pain. What diagnosis is the most reliable?
 - A. Acute arthritis of the right TMJ
 - B. Acute purulent parotitis
 - C. Dislocation of the lower jaw
 - D. Acute sialoadenitis
 - E. Arthrosis of the right TMJ.

3. A 10-year-old boy in 4 days after getting a trauma complains of a pain in the left half of the face, limited opening of a mouth. Objectively: considerable edema of tissues of the left infraorbital and parotid areas. A bite is not changed. The opening of the mouth is to 1.5 cm, at the attempt of subsequent motion of the lower jaw the pain increases and "mechanical" obstacle is present. The palpation of the left zygomaticus arch is painful. What is the most reliable diagnosis?
 - A. Traumatic arthritis of the left TMJ
 - B. Fracture of the left zygomaticus arch
 - C. Middle fracture of the maxilla
 - D. Fracture of the left articular processes
 - E. Subbasal fracture of the maxilla.

4. The 10 years old child complains of the acute severe pain in the left parotid area which increases during mouth opening. The pain irradiates into the ear and left temporal area. When mouth is closed the pain decreases. Objectively: edema and hyperemia in the area of the left TMJ are observed. X-ray:

expansion of the joint space. What clinical symptom can appear as defense reaction of masticatory muscles when acute arthritis of TMJ is taking place?

- A. Deviation of the lower jaw to the sound side
- B. Deviation of the lower jaw to the injured side
- C. S-like movements of the jaw
- D. Equable movements of the jaw
- E. The movements of the lower jaw are no restricted.

5. A 14-year-old boy complains of the pain in the right temporomandibular joint during the mouth opening, which appeared 3 weeks ago after the flu. Objectively: hyperaemia and swelling of tissues in the right area of the joint. The regional lymph nodes are enlarged. Body temperature is 37, 5 °C. Teeth are intact with orthognathic occlusion. On X-ray of the joint: the bone structure is not changed; the right joint ligament is increased. What is the most likely diagnosis?

- A. Acute arthritis of the right TMJ
- B. Chronic otitis
- C. Arthrosis-arthritis of the temporomandibular joint
- D. Chronic arthritis of the right TMJ
- E. Front luxation of the mandible.

PRACTICAL LESSON № 9

Theme. Traumatic injuries of the soft tissues. Burns and frostbites.

Aim of the lesson. To familiarize students with etiology and different types of soft tissue traumas in children, peculiarities of the clinical course, their treatment. To familiarize students with etiology and different types and stages of combustions and frostbites in children, their treatment.

Control of the initial level of knowledge

1. Definition of the trauma.
2. Anatomy and functional peculiarities of the structure of soft tissues of MFA in children.
3. Classification of the traumas of the soft tissues.
4. Definition of the combustion and frostbite.
5. Anatomy and functional peculiarities of the structure of soft tissues of MFA in children.
6. Classification of the combustions and frostbites in children.

Content of the lesson

The initial examination involves evaluating and stabilizing the trauma patient. Any life-threatening conditions should be identified and managed immediately. The conditions of the airway, breathing, and circulation are examined, followed by a general neurologic assessment with particular attention to cervical spine and cranial injuries.

It is important to achieve hemostasis when stabilizing and evaluating the patient who has sustained trauma. Most bleeding will respond to application of a pressure dressing. Occasionally surgical exploration and packing of the wound under general anesthesia may be indicated. In rare instances vessels in the neck may need to be ligated. Indiscriminate clamping inside the wound should be avoided because damage to important structures such as the facial nerve or parotid duct may occur. It is unusual for bleeding from soft tissue injuries of the face to result in a shock state. Lacerations involving the scalp can occasionally be difficult to control with pressure and may require clamping, ligation, or electrocautery.

In soft tissue injuries, not involving the face, the length of time from initial injury to treatment is important. Secondary risk of infection increases with the lapse of time.

Because of the rich vascularity of the face there is no “golden period” for suture repair of facial wounds. In fact healing of facial wounds is unaffected by the interval between injury and repair.

Patients who are immunized and have received a booster injection within the last 10 years do not require tetanus prophylaxis if the wound is not tetanus prone. Tetanus-prone wounds are those with heavy contamination with soil or manure, devitalized tissue, or deep puncture wounds. If the wound is tetanus prone and the patient has not received a booster injection within 5 years prior to the injury, a 0.5 ml tetanus toxoid boost injection should be given. If the patient has not received a booster within 10 years prior, they should receive a booster injection for any wound. Patients who are not immunized should receive both a booster injection and 250 units of tetanus immunoglobulin, followed by a full course of immunization.

Types of Injuries

Abrasions. Shear forces that remove a superficial layer of skin cause abrasions. The wound should be gently cleansed with a mild soap solution and irrigated with normal saline. These superficial injuries usually heal with local wound care. It is important to determine whether foreign bodies have been embedded in the wound. Failure to remove all foreign material can lead to permanent “tattooing” of the soft tissue. After the wound is cleansed the abrasion is covered with a thin layer of topical antibiotic ointment to minimize desiccation and secondary crusting of the wound. Reepithelialization without significant scarring is complete in 7 to 10 days if the epidermal pegs have not been completely removed. If the laceration significantly extends into the reticular dermal layer, significant scarring is likely.

Contusions. Contusions are caused by blunt trauma that causes edema and hematoma formation in the subcutaneous tissues. The associated soft tissue swelling and ecchymosis can be extensive. Small hematomas usually resolve without treatment; hypopigmentation or hyperpigmentation of the involved tissue can occur, but is rarely permanent. Large hematomas should be drained to prevent permanent pigmentary changes and secondary subcutaneous atrophy.

Lacerations. Lacerations are caused by sharp injuries of the soft tissue. Lacerations can have sharp, contused, ragged, or stellate margins. The depth of penetration should be carefully explored in the acute setting. Closure is performed using a layered technique. If the margins are bevelled or ragged, they should be conservatively excised to provide perpendicular skin edges to prevent excessive scar formation. Rarely there is an indication for changing the direction of the wound margins by Z-plasty at the time of primary wound repair. Flap-like lacerations occur when a component of the soft tissue has been elevated secondary to trauma. Eliminating dead space by layered closure and pressure dressings is especially important in these “trapdoor” injuries.

Avulsive Injuries. Avulsive injuries are characterized by the loss of segments of soft tissue. Undermining the adjacent tissue, followed by primary closure, can close small areas. When primary closure is not possible, other options are considered. These include local flaps or allowing the wound to heal by secondary intention followed by delayed soft tissue techniques. If a significant amount of soft tissue is missing, then a skin graft, local flaps, or free-tissue transfer may be necessary.

Animal and Human Bites. Dog bites are most common in children and the midface is frequently involved. Canines can generate 200 to 450 psi when biting, and examination for fractures should be performed.

Management of bite injuries involves liberal amounts of irrigation and meticulous primary closure.

Wound irrigation and debridement are important in reducing infection. Animal and human bites are most often polymicrobial, containing aerobic and anaerobic organisms. Dog bites are often open and lend themselves to vigorous irrigation and debridement. Cats have a large quantity of bacteria in their mouth, with the most frequent and important pathogen being *Pasteurella multocida*. Cat bites are associated with a two fold higher risk of infection than the more common dog bite wounds. Because their bites usually cause puncture wounds, they are difficult to clean. Having the patient follow up 24 to 48 hours after the initiation of therapy allows the surgeon to monitor the wound for any signs of

infection. Antibiotic prophylaxis for animal bites continues to be debated with few good prospective studies available. Amoxicillin-clavulanate is the current drug of choice for bite wounds. Antibiotic prophylaxis should be directed at *Pasteurella multocida* for infections present within 24 hours of injury.

For wounds that present after 24 hours of injury, *Streptococcus* and *Staphylococcus* species are more common, and antibiotic prophylaxis with a penicillinase-resistant antibiotic should be chosen.

Immediate closure of bite injuries is safe, even with old injuries. There is approximately a 6% rate of infection when bite wounds are sutured primarily in lacerations where there are cosmetic concerns. Extensive animal bite wounds involving the face should be treated according to the criteria of esthetic reconstructive surgery. Rabies prophylaxis should be given for bite wounds that occurred from an unprovoked domestic dog or cat that exhibits bizarre behaviour or from an attack of a wild animal such as a raccoon, skunk, bat, fox, or coyote.

Gunshot Wounds to the Face. Gunshot wounds require careful attention and evaluation of associated facial fractures. Both entry and exit wounds should be evaluated. Exit wounds often produce marked tissue destruction and require acute debridement. Regional flaps can be useful in treating facial soft tissue defects caused by gunshot wounds.

Ballistic facial injuries are grouped by etiology: gunshot, shotgun, and high-energy avulsive injuries.

Over the past 20 years advances in imaging and the introduction of craniofacial approaches with rigid fixation have led to an evolution of treating facial injuries. The esthetic and functional results of facial injury are improved dramatically by the combination of a definitive open reduction of bone with early replacement of soft tissue into its primary position. Immediate definitive reconstructions with rigid fixation of the facial fractures and closure of the lacerations are recommended. Standard incisions often need to be modified because of the soft tissue wounds.

Burns

Facial burns may occur alone or in association with burns of the trunk, when the patient is upright and the flames travel upwards to the head, neck and scalp. Oral burns are uncommon injuries which present more frequently in children. Associated inhalation or smoke injuries may occur. Pulmonary, thermal or toxic damage may occur. Associated blast injury may occur if the mode of injury is an explosion rather than domestic fire. Paediatric burns may be associated with accidental or non-accidental injury.

Immediate assessment of the burned patient

Depth of burning 1. 1st degree burn are usually caused by non-boiling liquids, limited sunlight exposure and some chemicals. They are erythematous, wet, painful and may blister. They are very sensitive to pin prick testing. They heal well from underlying and marginal epithelial tissues with little scarring or cosmetic impairment. With the exception of simple analgesia, little active treatment is usually required.

2. 2nd degree burn are usually caused by scalds from boiling liquids, flame burns and contact burns. They are usually very painful, mottled in appearance and may blister. They are less sensitive to pin prick testing than superficial burns but are hyperaesthetic to cold and air currents if the patient is transferred with an exposed wound. These burns will usually heal spontaneously from surviving epithelial and dermal remnants.

Hypertrophic scarring, contracture and poor cosmetics are major problems if the wound is not excised and grafted in the initial phase. Infection will impair healing and graft take.

3. 3rd degree burn, 2 stages: A and B are caused by some scald injuries particularly in children and the elderly. Contact burns in unconscious patients and high voltage electrical burns can be full thickness.

Stage 3A: Is characterised by partial necrosis of the skin with preserving of growth layer of epidermis and adnexae of skin. Total healing of the damaged skin may be achieved.

Stage 3B: These burns are typically painless and appear dark, sometimes charred and dry. They are typically insensate on pin prick testing. Untreated, they heal by slow secondary intention with much scarring. Epithelial appendages and skin adnexae are destroyed, which

renders the injury relatively pain free.

4.4th degree burn. The most severe burn as it extends to the deep fascia and destroys muscle and muscle groups and bones. It is characterized by charred scab with different thickness, dark colour and necrosis of the subjacent tissues.

The 'rule of nines' indicates the total body surface area affected by burn and accounts for surface area as a percentage; 9% each for arms and head, 18% each for legs, front and back of trunk, and 1% for the external genitalia. This scheme requires adjustment for children due to the relatively greater surface area of the head and face. An alternative scheme uses the patient's palmar surface area as 1% and describes burn area as a multiple. The calculation is important, as fluid replacement is calculated using the burn percentages as a basis.

Management

General

1. Airway management. Indications for airway support include deep burns of the face and neck, burns of the tongue and pharynx, stridor or hoarseness or near-encircling neck burns. Escharotomy may be required to permit airway protection from the inevitable oedema and to reduce the late threat to the airway due to scar contracture.

2. Restoration of the circulation. During the first 48 hours after a significant burn, the patient is hypovolaemic due to pericapillary tissue exudation and tissue oedema. Surface fluid loss does occur but is a minor contributor to the demand for fluid replacement. Pulmonary oedema in the elderly and cerebral oedema in the very young are significant risks. After about 48 hours, the patient becomes diuretic and fluid replacement demands fall. Urinary catheterization is

required and urine output should be maintained at 50 ml/hour. Adequate fluid replacement is monitored by documenting urine output, peripheral perfusion and temperature. The derived volume is given as colloid, usually human plasma protein fraction or salt-poor human albumin via IV infusion. The calculated volume is given three times in the first 12 hours, twice in the second 12 hours and once more in the third 12 hours after burning.

Analgesia. Opiates are often required in substantial doses. Regular parenteral infusions are necessary. Mixed opiate and simple analgesic regimens are commonly used.

Prevention of infection. Chemoprophylaxis does not completely eliminate the risk of bacterial sepsis, and may encourage the emergence of resistant strains or super-infection with *Candida* species. However, suspicion of Group A *P*-haemolytic streptococci is an

indication for antibiotics. Staphylococcal infection may lead to septic or endotoxic shock. This complication is an ever present threat in burned patients. Early IV fluids, fresh frozen plasma and appropriate antibiotics are life saving. Early coverage of burns by temporary dressings or grafts may reduce the risk of septic complications.

Frostbite is the medical condition in which localized damage is caused to skin and other tissues due to freezing. Frostbite is most likely to happen in body parts farthest from the heart and those with large exposed areas. The initial stages of frostbite are sometimes called frostnip.

Classification. There are several classifications for tissue damage caused by extreme cold including:

- Frostnip is a superficial cooling of tissues without cellular destruction.
- Chilblains are superficial ulcers of the skin that occur when a predisposed individual is repeatedly exposed to cold
- Frostbite involves tissue destruction.

Signs and symptoms.

At or below 0 °C (32 °F), blood vessels close to the skin start to constrict, and blood is shunted away from the extremities via the action of glomus bodies. The same response may also be a result of exposure to high winds. This constriction helps to preserve core body temperature. In extreme cold, or when the body is exposed to cold for long periods, this protective strategy can reduce blood flow in some areas of the body to dangerously low levels. This lack of blood leads to the eventual freezing and

death of skin tissue in the affected areas. There are four degrees of frostbite. Each of these degrees has varying degrees of pain.

First degree.

This is called frostnip and only affects the surface of the skin, which is frozen. On the onset, there is itching and pain, and then the skin develops white, red, and yellow patches and becomes numb. The area affected by frostnip usually does not become permanently damaged as only the skin's top layers are affected. Long-term insensitivity to both heat and cold can sometimes happen after suffering from frost nip.

Second degree.

If freezing continues, the skin may freeze and harden, but the deep tissues are not affected and remain soft and normal. Second-degree injury usually blisters 1–2 days after becoming frozen. The blisters may become hard and blackened, but usually appear worse than they are. Most of the injuries heal in one month, but the area may become permanently insensitive to both heat and cold.

Third and fourth degrees.

If the area freezes further, deep frostbite occurs. The muscles, tendons, blood vessels, and nerves all freeze. The skin is hard, feels waxy, and use of the area is lost temporarily, and in severe cases, permanently. The deep frostbite results in areas of purplish blisters which turn black and which are generally blood-filled. Nerve damage in the area can result in a loss of feeling. This extreme frostbite may result in fingers and toes being amputated if the area becomes infected with gangrene. If the frostbite has gone on untreated, they may fall off. The extent of the damage done to the area by the freezing process of the frostbite may take several months to assess, and this often delays surgery to remove the dead tissue.

Treatment.

The decision to thaw is based on proximity to a stable, warm environment. If rewarmed tissue ends up refreezing, more damage to tissue will be done. Excessive movement of frostbitten tissue can cause ice crystals that have formed in the tissue to do further damage. Splinting and/or wrapping frostbitten extremities are therefore recommended to prevent such movement. For this reason, rubbing, massaging, shaking, or otherwise applying physical force to frostbitten tissues in an attempt to rewarm them can be harmful.

Warming can be achieved in one of two ways:

Passive rewarming involves using body heat or ambient room temperature to aid the person's body in rewarming itself. This includes wrapping in blankets or moving to a warmer environment.

Active rewarming is the direct addition of heat to a person, usually in addition to the treatments included in passive rewarming. Active rewarming requires more equipment, and therefore may be difficult to perform in the prehospital environment. When performed, active rewarming seeks to warm the injured tissue as quickly as possible without burning. This is desirable, because the faster tissue is thawed, the less tissue damage occurs. Active rewarming is usually achieved by immersing the injured tissue in a water-bath that is held between 40-42°C (104-108F). Warming of peripheral tissues can increase blood flow from these areas back to the body's core. This may produce a decrease in the body's core temperature and increase the risk of cardiac dysrhythmias.

Knowledge level control:

1. Classification of injuries of the soft tissues of MFR in children.
2. Peculiarities of child examination with injuries of the soft tissues.
3. Methods of treatment of the injuries of the soft tissues.
4. Main principles of the primary surgical wound processing.
5. Dispenserization and rehabilitation of the patient with injuries of MFA.
6. Prevention of the traumas.
7. First aid and treatment of the thermal and chemical injuries of the soft tissues
8. Stages of combustions.
9. Stages of frostbites.
10. Clinical pictures of different stages of combustions.

11. Clinical pictures of different stages of frostbites.
12. Principles of treatment of combustions and frostbites.

Tests

1. 7 years old girl admitted to the maxillofacial hospital with bitten wound of the cheek. Determine what kind of wounds should be necessarily drained:
 - A. All listed
 - B. Bitten wounds
 - C. Stab wounds
 - D. Deep wounds (gash)
 - E. Wounds that penetrate into the oral cavity

2. 5 years old boy was delivered to the maxillofacial hospital with superficial wound of the face. What wound of the soft tissue can heal without scarring?
 - A. Scratches
 - B. Superficial wounds
 - C. Deep wounds (gash)
 - D. Permeable wounds
 - E. Stab wounds

3. 5 years old girl with lacerated wound of the soft palate came to the maxillofacial hospital. Select the type of anesthesia for primary surgical debridement of the wound:
 - A. Endotracheal anesthesia
 - B. Intravenous anesthesia
 - C. Conduction anesthesia
 - D. Infiltration anesthesia
 - E. Topical anesthesia

4. 4 years old girl admitted to the maxillofacial hospital with bitten wound of the cheek. Determine in what cases it is necessary to conduct anti-rabies vaccination:
 - A. In all cases,
 - B. A dog that bit was not found
 - C. A dog lives in the area, unfavorable about rabies
 - D. The dog is known but not vaccinated against rabies
 - E. The dog that bit, was diagnosed with rabies

5. 14 years old patient appealed to the dentist with cut wound on the left buccal area which he received 2 hours ago as a result of the fall. What type of sutures should be performed during surgical debridement of the wound in this patient?
 - A. Primary with drainage
 - B. Plate sutures
 - C. No sutures should be performed
 - D. Secondary
 - E. Secondary delayed

PRACTICAL LESSON № 10

Theme. Furuncles and carbuncle of the maxillofacial area. Classification, diagnosis, differential diagnosis, treatment. Complications and its prevention. Summary lesson. Differentiated test.

Aim of the lesson. To familiarize students with peculiarities of the clinical course of the furuncles and carbuncles of the MFA in children, treatment.

Control of the initial level of knowledge

1. Anatomical and physiological characteristics of the skin in children.
2. Anatomical and physiological characteristics of the soft tissues in children.
3. Main stages of development of child's organism.

Content of the lesson

A **boil**, also called a **furuncle**, is a deep folliculitis, infection of the hair follicle. It is most commonly caused by infection by the bacterium *Staphylococcus aureus*, resulting in a painful swollen area on the skin caused by an accumulation of pus and dead tissue. Individual boils clustered together are called carbuncles. Most human infections are caused by coagulase-positive *S. aureus* strains, notable for the bacteria's ability to produce coagulase, an enzyme that can clot blood. Almost any organ system can be infected by *S. aureus*.

Boils are bumpy, red, pus-filled lumps around a hair follicle that are tender, warm, and very painful. They range from pea-sized to golf ball-sized. A yellow or white point at the center of the lump can be seen when the boil is ready to drain or discharge pus. In a severe infection, an individual may experience fever, swollen lymph nodes, and fatigue. A recurring boil is called chronic furunculosis. Skin infections tend to be recurrent in many patients and often spread to other family members. Systemic factors that lower resistance commonly are detectable, including: diabetes, obesity, and hematologic disorders.

Usually, the cause is bacteria such as staphylococci that are present on the skin. Bacterial colonization begins in the hair follicles and can cause local cellulitis and inflammation. Patients with recurrent boils are as well more likely to have a positive family history, take antibiotics, and to have been hospitalized, anemic, or diabetic; they are also more likely to have associated skin diseases and multiple lesions.

The most common complications of boils are scarring and infection or abscess of the skin, spinal cord, brain, kidneys, or other organs. Infections may also spread to the bloodstream (bacteremia) and become life-threatening. *S. aureus* strains first infect the skin and its structures (for example, sebaceous glands, hair follicles) or invade damaged skin (cuts, abrasions). Sometimes the infections are relatively limited (such as boil, furuncle, or carbuncle), but other times they may spread to other skin areas (causing cellulitis, folliculitis or impetigo). Unfortunately, these bacteria can reach the bloodstream (bacteremia) and end up in many different body sites, causing infections (wound infections, abscesses, osteomyelitis, endocarditis, and pneumonia) that may severely harm or kill the infected person. *S. aureus* strains also produce enzymes and exotoxins that likely cause or increase the severity of certain diseases. Such diseases include food poisoning, septic shock, toxic shock syndrome, and scalded skin syndrome. Almost any organ system can be infected by *S. aureus*.

Treatment

A small boil may burst and drain on its own without any assistance. In some instances, however, draining can be encouraged by application of a cloth soaked in warm salt water (warm compresses).

Washing and covering the furuncle with antibiotic cream or antiseptic tea tree oil and a bandage also promotes healing.

Furuncles at risk of leading to serious complications should be incised and drained by a medical practitioner. These include furuncles that are unusually large, last longer than two weeks, or are located in the middle of the face or near the spine.¹ Fever and chills are signs of sepsis that require immediate treatment.

Antibiotic therapy is advisable for large or recurrent boils or those that occur in sensitive areas (such as around or in the nostrils or in the ear). *Staphylococcus aureus* has the ability to acquire antimicrobial resistance easily, making treatment difficult. Knowledge of the antimicrobial resistance of *S. aureus* is important in the selection of antimicrobials for treatment. Poor personal hygiene being common, the role of nasal *S. aureus* carrier may differ from communities with good hygienic practices. *Staphylococcus aureus* re-infection may result from contact with infected family members, contaminated fomites, or from other extra-nasal sites. This raises a suggestion to treat household contacts and close contacts if recurrence persists, because it is likely that one or more contacts are asymptomatic carriers of *S. aureus*. In addition to the increase in the cost of treatment in poor countries, the possibility of developing drug resistance must be considered. The most important independent predictor of recurrence is a positive family history. Boils are spread among individuals by touching or bursting a boil. The role of iron deficiency anemia in recurrent furunculosis was demonstrated, all patients were free from recurrence during the six months follow-up period after iron supplementation. A variety of host factors, such as abnormal neutrophil chemotaxis, deficient intracellular killing, and immuno-deficient states are of importance in a minority of patients with recurrent furunculosis. Health education about sound personal hygiene and correction of anemia should be mandatory in management of furunculosis. It was found that recurrence was significantly associated with poor personal hygiene. A previous study reported that MRSA infection was significantly associated with poor personal hygiene. It was reported that frequent hand and body washing with water and antimicrobial soap solution decreases staphylococcus skin colonization. Previous use of antibiotics is associated with a high risk of recurrence. This may be due to the development of resistance to the antibiotics used. An associated skin disease favors recurrence. This may be attributed to the persistent colonization of abnormal skin with *S. aureus* strains, such as is the case in patients with atopic dermatitis.

Carbuncle

A carbuncle is an abscess larger than a boil, usually with one or more openings draining pus onto the skin. It is usually caused by bacterial infection, most commonly *Staphylococcus aureus*, or *Streptococcus namo kines*, which can turn lethal. However, the presence of carbuncles is actually a sign that the immune system is working. The infection is contagious and may spread to other areas of the body, or other people; those living in the same residence may develop carbuncles at the same time. A carbuncle is made up of several skin boils. The infected mass is filled with fluid, pus and dead tissue. Fluid may drain out of the carbuncle, but sometimes the mass is so deep that it cannot drain on its own.

The carbuncle may be the size of a pea or as large as a golf ball. It may be red and irritated, and might hurt when touched. It may also grow very fast and have a white or yellow center. It may crust or spread to other skin areas. Sometimes other symptoms may occur, such as fatigue, fever and a general discomfort or sick feeling. Itching may occur before the carbuncle develops.

Treatment

Oral antibiotics against the gram positive bacteria is recommended when the boil is larger than 5 cm diameter, or 2 cm proud (tall), or very painful, or appearing to (or actually is) spread to new sites, or entered below the skin into underlying structure, such as causing a painful muscle, bone, ligament or joint, or if the lymph nodes are inflamed. Oral antibiotics will treat the carbuncle and antibiotics should be continued until the carbuncle has healed over.

Streptococcus pyogenes in the blood stream is noted as a common cause of rheumatic fever (and hence arthritis), and also heart valve failure, so waiting for a natural cure is not recommended. Any

bacterial infection serious enough to cause a large boil can, rarely, lead to blood poisoning or spread to other organs (eg. joints, lungs, brain), and in fact any other body part.

Without antibiotic treatment, carbuncles usually must drain before they will heal.

If left untreated, within two weeks the skin weakens and perforates and the contents explode out, this apparently being caused by the immune system ramping up its repulsion of the bacteria.

Placing a warm moist cloth on the carbuncle and soaking the affected area several times each day helps it to drain, which speeds healing. Squeezing the carbuncle, or cutting it open without medical supervision (and without oral antibiotics effective against the gram positive bacteria) can spread and worsen the infection.

Treatment is certainly needed if the carbuncle lasts longer than two weeks, returns frequently, is located on the spine or the middle of the face, or occurs along with a fever or other symptoms. Treatment helps reduce complications related to an infection. A doctor may prescribe antibacterial soaps, as a preventative for the future, and antibiotics applied to the skin or taken by mouth. Deep or large lesions may need to be drained by a health professional. Proper excision by cruciate incision under strict aseptic conditions will usually treat the condition effectively, but the modern practice is to use antibiotics.

Proper hygiene is very important to prevent the spread of infection. Hands should

always be washed thoroughly, preferably with antibacterial soap, after touching a daily use of an antibacterial soap or cleanser containing triclosan, triclocarban or chlorhexidine, can suppress staph bacteria on the skin. The bacteria may not remain inside the boil or carbuncle; it may progress to inside the skin, into underlying tissues. This may occur more often where the boil is on the buttocks or back or upper arm, where the patient may squash the boil and cause the fluids inside to explode their cyst-like containment. This may lead to further boils and carbuncles (or arms, like a mountain ridge branching off existing sites); cellulitis (where the skin appears to be covering infected flesh); infected lymph nodes (which are sore to the touch) and, in fact, infection of any other body part; and the infection causes the person to feel nauseated, fevered, dizzy, weak, lethargic, breathless, unhealthy of the heart, headaches, or (in the worst case) death.

Knowledge level control

1. Causes of boils and carbuncles.
2. The clinical picture of boils and carbuncles.
3. Differential diagnosis of boils and carbuncles.
4. Treatment of boils and carbuncles.
5. Indications for surgical intervention in boils and carbuncles.
6. Complications of boils and carbuncles.
7. Prevention of boils and carbuncles appearance.

Tests

1. A 12- year-old girl has 2.2 cm edema on the right cheek area . The skin above is blushed. The necrotizing core is formed in the center of the edema. The temperature is 38.2°C and the intoxication is presented. What is the most reliable diagnosis?

- A. Abscessed furuncle of the right buccal area
- B. Phlegmon of the right buccal area
- C. Acute purulent nonodontogenic lymphadenitis of the right cheek area
- D. Nonodontogenic abscess of the right buccal area
- E. Purulent atheroma of the right buccal area

2. 16 years old patient appealed to the doctor with complaints on a swelling in the left frontal area , headache , weakness , fever up to 38,3 ° C. The duration of disease is 3 days. The patient was treated at home with warming packs. Objectively: tissue edema of frontal area and the eye area on the left side; eye slit is narrowed by swelling of eyelids. In the frontal area on the left side there is a thick cone-

shaped infiltrate up to 2x2 cm , painful on palpation ,with purulent crusts in the centre. The skin is hyperemic. Clarify the diagnosis:

- A. Boil(furuncle) of the frontal area on the left side
- B. Carbuncle of the frontal area on the left side
- C. Phlegmon of the frontal area on the left side
- D. Dermoid cyst of the frontal area on the left side
- E. Atheroma of the frontal area on the left side

3.Patient of 17 years old was diagnosed with furuncle of the upper lip. After opening of the inflammatory focus the bacteriological examination of the fluid was conducted. What pathogen culture can be detected in this study?

- A. Monoculture of staphylococcus
- B. Monoculture of intestinal bacillus
- C. Monoculture of Proteus
- D. Association of staphylococcus and simplest
- E. Monoculture of streptococcus

4.During examination of the patientthe sharply painful, limited infiltration that rises above the healthy skin on the upper lip was revealed. The infiltration has conical shape with purulent necrotic core in the center. The body temperature rises up to 39 ° C.The patient was illduring 4 days. Clarifythe diagnosis:

- A. Furuncle
- B. Carbuncle
- C. Abscess of the buccal area
- D. Deep folliculitis
- E. Siberia, ulcerative carbuncle

5. Patient of 18 years old was diagnosed with the furuncle, in the left angle of the mandible. Surrounding tissues are tense. Cyanosis and seals that look like cord extends till the corner of the eye. Overall condition is severe; body temperature is 38, 9 ° C. What complication is observed in the patient?

- A. Facial vein thrombophlebitis
- B. Abscess of the buccal area
- C. Phlegmon of the buccal area
- D. Acute sinusitis
- E. Carbuncle of the buccal area

Control questions (differentiated test):

1. Anatomical and physiological features of the structure of soft tissues and jaws.
2. Features of innervation of the maxillofacial area (MFR).
3. Features of the location of the saline orifice and the exit of the neurovascular bundles on the bones, depending on the age of the child.
4. Indications and contraindications to the local types of anesthesia of the tissues of the(MFR) (application, infiltration, conductor).
5. Modern local painkillers, their choice, ways of determining the tolerability of anesthetics.
6. The algorithm of conducting anesthesia in children of all ages.
7. Local and general complications of anesthesia, their prevention and treatment.
8. Indications for surgical intervention in MFR in children using general anesthesia.

9. Anatomical features of the structure of primary and permanent teeth, jaws, their innervation and vascularization.
10. The timing of physiological tooth changes in children.
11. Impressions and contraindications for primary teeth removal in children.
12. Indications and contraindications for permanent teeth extraction in children.
13. Surgical tools for teeth removal in children.
14. Steps of extraction of teeth.
15. Features of the method of extraction of primary and permanent teeth.
16. Local complications during and after tooth extraction, prevention and treatment.
17. Features of teeth extraction in children with diseases of the cardiovascular and endocrine systems, as well as with diseases of the blood system.
18. Features of structure and development of jaws and jaw soft tissues in children of all ages and their effect on the course of inflammatory processes.
19. Clinical course of acute and chronic periostitis of odontogenic and non-odontogenic origin.
20. Clinical and laboratory criteria for the differential diagnosis of acute and chronic periostitis.
21. Laboratory examination and interpretation of the results of a study of a child with jaw periostitis.
22. Methods of anesthesia for performing periostotomy.
23. Principles of surgical treatment of jaw periostitis.
24. Principles of medical treatment of jaw periostitis.
25. Indications and methods of physiotherapy treatment of jaw periostitis.
26. Prevention of complications.
27. Features of structure, development, vascularization and innervation of jaw bones and surrounding soft jaws in children of all ages.
28. Etiology and pathogenesis of an acute osteomyelitis.
29. Clinical course of acute osteomyelitis of odontogenic and non-odontogenic origin.
30. Criteria for the diagnosis and differential diagnosis of acute bone inflammatory processes.
31. X-ray signs in osteomyelitis of the jaws.
32. Methods of laboratory examination of a child with jaw osteomyelitis.
33. Complex treatment of osteomyelitis of the jaws of different genesis and course.
34. Features of surgical treatment of acute jaw osteomyelitis.
35. Complications for acute osteomyelitis and their prevention.
36. Etiology and pathogenesis of chronic osteomyelitis.
37. Clinical course of chronic osteomyelitis of odontogenic and non-odontogenic origin.
38. Criteria for the diagnosis and differential diagnosis of chronic bone inflammatory processes.
39. X-ray signs in osteomyelitis of the jaws.
40. Methods of laboratory examination of a child with jaw osteomyelitis.
41. Complex treatment of osteomyelitis of the jaws of different genesis and course.
42. Features of surgical treatment of chronic osteomyelitis of the jaws.
43. Complications of chronic osteomyelitis and their prevention.
44. Features of the structure of the lymphatic system in children.
45. Topographic-anatomical distribution of groups of lymph nodes of MFR
46. Features of the course of inflammatory processes of soft tissues in children.
47. Definition of terms "lymphadenitis", "periadenitis", "adenoflegmon".
48. Classification of MFR lymphadenitis by etiological factor, depth of location, anatomic-topographic location, clinical course.
49. Examination methods for a child with acute and chronic thyroid lymphadenitis.
50. Clinical manifestations of various forms of MFR lymphadenitis.
51. Features of clinical manifestations of diseases with which differential diagnosis of lymphadenitis is carried out.
52. Normal peripheral blood composition in children of all ages and changes in lymphadenitis.
53. Additional methods of diagnosis of lymph nodes in children.

54. General provisions for the surgical treatment of MFR adeno-abscesses and incision line depending on their location.
55. Phases of wound healing after opening of the adeno abscess.
56. Principles of drug therapy for acute and chronic lymphadenitis.
57. Physiotherapy methods for the treatment of acute and chronic MFR lymphadenitis.
58. Topographic and anatomical areas of the face, their borders and connections.
59. Features of the course of inflammatory processes of soft tissues in children.
60. Definition of terms "inflammatory infiltrate", "edema", "abscess", "phlegmon", "adenoabscess", "adenoflegmon".
61. Classification of abscesses and phlegmon of the MFR gland by pathogen penetration, depth of location, anatomic-topographic location around the jaws.
62. Use of additional research methods and indications for their conduct.
63. The normal composition of peripheral blood in children of all ages and changes in abscess and phlegmon.
64. Clinical manifestations of superficial and deep abscesses and phlegmon of MFR.
65. Clinical manifestations of diseases with which differential diagnosis of abscesses and phlegmon are carried out.
66. Complications of abscesses and phlegmon of different localization.
67. General provisions of surgical treatment of abscesses and phlegmon of MFR. Abscess opening lines and phlegmon depending on their location. Types of drainage.
68. Phases of the wound process, their characteristics, preparations used in different phases.
69. Principles of drug therapy for abscesses and phlegmon.
70. Physiotherapy treatment for abscesses and phlegmon.
71. Features of the anatomical and functional structure of the TMJ depending on the child's age.
72. Definition of the terms "arthritis", "contracture", "ankylosis", "secondary deforming osteoarthritis".
73. The main etiological factors for the occurrence of acute and chronic diseases of the TMJ.
74. The main clinical manifestations of acute and chronic arthritis, secondary deformable osteoarthritis, ankylosis.
75. Basic and additional methods of examination of a child with diseases of the TMJ.
76. X-ray picture of the TMJ is normal, and its changes in acute and chronic diseases.
77. Treatment tactics for acute and chronic diseases of the TMJ.
78. Groups of medicines used in the treatment of acute and chronic inflammatory processes of the TMJ, the mechanism of their action.
79. Physiotherapy methods for the treatment of TMJ diseases.
80. Principles of surgery for deforming osteoarthritis and ankylosis.
81. Complications of TMJ diseases and their prevention.
82. Topographic anatomy and location of the excretory ducts of the large and small salivary glands.
83. Classification of inflammatory diseases of the salivary glands in children.
84. Etiological factors leading to inflammatory diseases of the salivary glands in children and methods of their prevention.
85. Clinical manifestations and differential diagnosis of acute and chronic inflammatory diseases of the salivary glands in children.
86. Clinical manifestations of diseases with which differential diagnosis of inflammatory diseases of salivary glands.
87. Examination methods for patients with salivary gland diseases.
88. Principles of treatment and rehabilitation of patients with acute and chronic inflammatory diseases of the salivary glands.
89. Topographic and anatomical areas of the face, their borders and connections.
90. Features of the course of furuncles, carbuncles with localization in the MFR.
91. Definition of terms "furuncles", "carbuncles", "furunculosis".
92. Classification of furuncles, carbuncles of MFR.

93. Clinical manifestations of furuncles and carbuncles of MFR. The normal composition of peripheral blood in children of all ages and changes in its indicators in case of presence furuncles, carbuncles of the MFR.
94. General provisions for the surgical treatment of Furuncles and carbuncles of the MFR, the incision line depending on their location.
95. Principles of drug therapy of furuncles, carbuncles of thyroid
96. Application of physiotherapy methods of treatment of furuncles, mechanism of their action and purpose depending on the course of the process.
97. Complications of furuncles, carbuncles of MFR and their prevention.
98. As a result of studying the discipline "Pediatric Dental Surgery" the student should be able to:
99. To conduct a clinical examination of the patient. Determine the indications and contraindications to the type of anesthesia required surgery.
100. To choose a method of local anesthesia according to the age of the child and the required surgery.
101. To be able to carry out an anesthetic allergy test and evaluate its result.
102. To have the technique of performing injection anesthesia, taking into account the age of the child and the type of surgery.
103. To carry out preventative measures and treatment of complications that may occur during and after anesthesia.
104. To conduct a clinical examination of the patient. Determine the indications and contraindications for tooth extraction.
105. Select a surgical instruments to remove a tooth according to its anatomical structure.
106. Provide guidance to the child's parents after the tooth removal surgery.
107. Prepare a plan for preliminary preparation for tooth extraction in children with comorbid somatic diseases.
108. Select instruments and stop bleeding that occurred during and after tooth extraction.
109. Carry out preventative measures and treatment of local complications that occur during and after tooth extraction.
110. Examine the child with jaw disease.
111. Prescribe and interpret the results of a radiological examination of a patient with chronic and acute periostitis.
112. To appoint and evaluate the results of laboratory tests of a child with acute periostitis.
113. Plan a treatment for a child with acute and chronic jaw periostitis.
114. Determine indications for endodontic treatment or removal "causative" tooth in case of odontogenic periostitis.
115. Determine the type of anesthesia for surgery in a child with periostitis. To conduct a conduction and infiltration anesthesia.
116. Perform the tooth extraction and periostotomy, cell drainage.
117. Prescribe drug therapy as indicated.
118. Develop a plan for rehabilitation of a child with acute and chronic jaw periostitis.
119. Diagnose acute odontogenic osteomyelitis of the jaws.
120. Diagnose acute hematogenous osteomyelitis of the jaws.
121. Carry out differential diagnosis of acute osteomyelitis of the jaws with periostitis, abscesses, phlegmon of the respective localizations, Ewing sarcoma.
122. Evaluate the results of laboratory and radiological examinations for osteomyelitis of the jaws.
123. Prescribe a complex of therapeutic measures for acute osteomyelitis.
124. Determine therapeutic tactics for acute hematogenous osteomyelitis of the jaws.
125. Choose the method of analgesia in the treatment of acute osteomyelitis.
126. Perform causative tooth removal and jaw periostotomy in the treatment of acute osteomyelitis.
127. Diagnose chronic odontogenic osteomyelitis of the jaws.
128. Carry out differential diagnosis of exacerbation of chronic jaw osteomyelitis with periostitis, abscesses, phlegmon of appropriate localization, Ewing sarcoma.

129. Perform differential diagnosis of chronic odontogenic osteomyelitis of the jaws in children with tumors and tumor-like neoplasms of odontogenic and osteogenic origin.
130. Evaluate the results of laboratory and radiological examinations for osteomyelitis of the jaws.
131. Prescribe a set of therapeutic measures for chronic osteomyelitis.
132. Choose a method of analgesia in the treatment of chronic osteomyelitis.
133. Perform causative tooth removal and jaw periostotomy in the treatment of chronic osteomyelitis.
134. Examine the main groups of lymph nodes in children.
135. Detect signs of inflammation of the lymph node.
136. Decrypt additional research methods (blood, urine, ultrasound).
137. Diagnose acute serous and acute purulent lymphadenitis.
138. Diagnose chronic hyperplastic lymphadenitis.
139. Diagnose chronic purulent lymphadenitis.
140. Perform differential diagnosis of acute serous and acute purulent lymphadenitis with each other.
141. Perform differential diagnosis of chronic forms of lymphadenitis among themselves, with tumors, neoplasms, or metastases of the malignant tumor.
142. To prescribe comprehensive treatment for a child with acute lymphadenitis.
143. Choose a treatment strategy for chronic hyperplastic lymphadenitis.
144. Examine the child with an abscess and phlegmon.
145. Prescribe and analyze the results of blood and urine testing of children at different ages and depending on the course of the inflammatory process.
146. Perform differential diagnosis of superficial and deep abscesses and phlegmon of MFR.
147. To choose surgical tactics for the treatment of abscesses and phlegmon of MFR of different localization.
148. To open the surface of abscesses with localization within one area, to establish and replace the drainage.
149. To prescribe complex medical therapy for children with abscesses and phlegmons of MFR.
150. Choose drugs for topical treatment of abscesses and phlegmon based on the phase of the wound process.
151. Prescribe physiotherapy treatments depending on the phase of the wound process.
152. Conduct a clinical examination of a child with a disease of the TMJ (survey, examination, palpation, determine the volume of movements).
153. Assign additional survey methods and interpret their data (orthopantomogram, MRI, CT, 3DKT).
154. Carry out differential diagnosis of acute and chronic inflammatory diseases of the TMJ.
155. Determine therapeutic tactics for acute and chronic inflammatory diseases of the TMJ, depending on the age of the child.
156. Determine therapeutic tactics for bone ankylosis.
157. Be able to examine a child who has signs of salivary gland disease.
158. Be able to diagnose the presence of an inflammatory process in the salivary gland (epidemic, viral, bacterial sialadenitis; parenchymatous and interstitial sialadenitis, calculous submaxylitis).
159. Differential diagnosis between acute and chronic sialadenitis, etc. inflammatory diseases of this area, as well as tumors, tumors of neoplasms of this localization.
160. Be able to interpret the results of additional methods of diagnosis in diseases of the salivary glands (laboratory parameters of blood, saliva; ultrasound; sialography).
161. To prescribe the scheme of treatment for acute diseases of the salivary glands (epidemic, viral, bacterial sialadenitis).
162. Assign a treatment regimen for chronic salivary gland diseases (parenchymal and interstitial sialadenitis, calculous submaxylitis).
163. To carry out preventive medical measures for chronic diseases of the salivary glands.
164. Carry out a child examination and diagnose furuncles of MFR and carbuncles in children.
165. Carry out differential diagnosis between boils and carbuncles of thyroid.
166. Perform differential diagnosis between abscess (phlegmon) and boils (carbuncle) of the MFR.
167. Assign additional survey methods and evaluate their results.

168. Choose treatment conditions, surgical tactics, method of anesthesia.
169. Prescribe medication for children with furuncles and carbuncles of thyroid.
170. Prescribe physiotherapy methods for the treatment of furuncles and carbuncles, depending on the clinical course.
171. Prevent complications of furuncles and carbuncles.

List of practical skills:

1. To demonstrate on the phantoms performing of the anesthesia when removing teeth in children.
2. To choose and demonstrate on the phantoms the ability to apply basic dental tools and use it in pediatric dentistry when:
 - removal of primary and permanent teeth;
 - opening of periosteal abscesses on the upper and lower jaws;
3. To distinguish features of application of principles of asepsis and antiseptic in the pediatric clinic dentistry.

Recommended literature:

1. Pediatric Oral and Maxillofacial Surgery: textbook. — 2nd edition / L.V. Kharkov, L.M. Yakovenko, N.V. Kiselyova. — K., 2020. — 104 p. + 24 p. colour insert.
2. Michael Miloro, 2004 London PETERSON'S PRINCIPLES OF ORAL AND MAXILLOFACIAL SURGERY Second Edition
3. Pediatric Oral and Maxillofacial Surgery Leonard B. Kaban, Maria J. Troulis, 2004.

Recommended literature:

1. Pediatric Oral and Maxillofacial Surgery: textbook. — 2nd edition / L.V. Kharkov, L.M. Yakovenko, N.V. Kiselyova. — K., 2020. — 104 p. + 24 p. colour insert.
2. Michael Miloro, 2004 London PETERSON'S PRINCIPLES OF ORAL AND MAXILLOFACIAL SURGERY Second Edition
3. Pediatric Oral and Maxillofacial Surgery Leonard B. Kaban, Maria J. Troulis, 2004.