

Danylo Halytsky Lviv National Medical University  
Pediatric Dentistry Department

**Methodological Recommendations  
for  
Pediatric Surgery Dentistry  
for the 5<sup>th</sup> year students**

Lviv 2021

**Composed by:** Oksana V. Skybchyk, assist.  
Olga B. Hrynyshyn, assist., PhD.  
Victoria L. Kostura, assist., PhD.  
Mykola B. Fur, assist., PhD.

**Reviewed by:** N. L. Chukhray. Prof., PhD  
O.R. Ripetska, Assoc. Prof., PhD  
Manyuk L.V., senior lecturer

**Chief Editor:** Kolesnichenko O.V., Assoc. Prof., PhD

Considered and approved on meeting of Pediatric Dentistry Department (protocol № 7, from 09.04.2021) and Profiled Methodical Commission of Dental faculty (protocol № 2, from 29.04.2021)

**Methodical recommendations were discussed, re-approved and confirmed at the meeting of the Department of Pediatric Dentistry of Lviv National Medical University named after Danylo Halytsky**

**Protocol №            from   «   » \_\_\_\_\_ 202**

**Protocol №            from   «   » \_\_\_\_\_ 202**

**Protocol №            from   «   » \_\_\_\_\_ 202**

**Protocol №            from   «   » \_\_\_\_\_ 202**

**Protocol №            from   «   » \_\_\_\_\_ 202**

**Responsible for the issue  
Vice-Rector for Academic Affairs, Professor M.R. Grzegotskyy**

THE PRACTICAL CLASSES SCHEDULE (SURGERY)  
(for the fifth year students of Dentistry Department, 9-10 th term)

№	Theme of the lesson	Hours
1	<p><b>Instruction on prevention of coronavirus infection (COVID-19), observance of rules of respiratory hygiene and anti-epidemic measures. Rules for the use and disposal of personal protective equipment. Symptoms of acute respiratory disease COVID-19 caused by coronavirus SARS-CoV-2.</b></p> <p>Benign tumors of the soft tissues of Oral- Facial Area in children (hemangioma and lymphangioma, lipoma, fibroma, mioma, nevus). Tumor-like neoplasm of soft tissues of the face (epidermoid and dermoid cysts, teratoma, atheroma, papilloma). Innate middle and lateral cyst and fistulae of neck. Neurofibromatosis.</p>	6
2	<p>True tumors and tumor-like neoplasms of the salivary glands. Osteogenic tumors of the bones (Giant-cell tumor of bone, Osteoma, Osteoid-osteoma). Odontogenic neoplasm of jaws in children (Ameloblastoma, Odontoma, Cementoma).</p>	6
3	<p>Tumor-like neoplasm of the jaw – cysts (follicular, residual, fissural, primary bone cyst and eruption cysts). Methods of diagnosis, diff. diagnosis. Surgical methods of treatment. Rehabilitation of the patients after cystectomy, cystotomy intervention. Tumor -like neoplasms of Jaws: Fibro-osseous Dysplasia, Ordinary congenital epulis, Cherubism, McCune–Albright syndrome.</p>	6
4	<p>Malignant Tumors of Oral-Facial Area in Children.</p>	6
5	<p>Diagnostic criteria of the benign tumors and tumor-like neoplasms of the maxilla-facial area in children. Principles of the doctor's tactics and rehabilitation on the different stages of treatment.</p>	6
6	<p>Congenital malformations of maxillo-facial area. Cleft of lip and palate. Short frenulum of lip and tongue. Shallow vestibulum oris. Rehabilitation of children with cleft lip and palate.</p>	6
7	<p>Congenital malformations of maxillo-facial area. Short frenulum of lip and tongue. Shallow vestibulum oris. Rehabilitation of children with cleft lip and palate. Some concomitant nonunion of the upper lip and palate: maxillo-facial area syndromes.</p>	
8	<p>Traumatic injuries of bones of maxillo-facial area in children. Pathognomonic clinical signs of the traumatic injuries of the maxillo-facial area in children. Methods of diagnosis.</p>	6
9	<p>Peculiarities of the clinical course, algorithms of diagnosis, treatment and prevention measures. The choice of the methods of the anesthesia in children with inflammation and somatic diseases of the maxillo-facial area.</p>	6
10	<p>Medical history of disease. Summary lesson. <b>Control of mastering practical skills.</b></p>	6
Whole		54

**The Independent Work Schedule  
(Surgery)**  
(for the fifth year students of Dentistry Department, 9-10th term ).

<b>№</b>	<b>Theme of the lessons</b>	<b>Hours</b>
1	Tumor processes in the maxillofacial area in children. Distribution of tumors face and jaws in children according to the international histological WHO classification.	2
2	Precancerous processes in the maxillofacial area in children. Distribution tumor-like neoplasms of the face and jaws in children according to WHO International Histological Classification.	2
3	Write the principles of prevention of oncostomatological pathology in children.	3
4	Principles of dental care in pediatric dentistry	3
5	Prevention of infection with specific diseases (tuberculosis, syphilis, AIDS and HIV - infection) by a dentist on an outpatient basis and in an inpatient setting.	3
6	Treatment and prevention of pathological scars after surgery interventions in maxillofacial area in children.	3
7	Describe the accompanying maxillofacial syndromes clefts of the upper lip and palate	3
8	Make a table of care for patients with injuries of the maxillofacial area.	3
9	Emergencies in the pediatric surgical dentistry clinic.	2
10	Preparing to write medical histories.	6
	In total	26

**Practical class 1**

**Benign tumors of the soft tissues of Oral- Facial Area in Children.**

Vascular Tumors of Oral-Facial Area. Classification. Etiology. Diagnosis, diff. diagnosis of hemangioma and lymphangioma. Methods of their treatment. Complications. Prevention. Indications for the blood substitute therapy due to surgical intervention of vascular tumors in children.

Clinical features, diagnosis, diff. diagnosis and treatment of lipoma, fibroma, mioma.

*Teaching objective:* to familiarize students with clinical course, diagnosis, treatment of benign tumours of the soft tissues in children.

**Pre-study test questions:**

1. Scheme of clarifying of clinical diagnosis of tumours of maxillo-facial area in children.
2. The main methods of treatment of neoplasm.
3. The main principles of surgical treatment of neoplasm in children.
4. Theory of the development of vascular lesions.
5. The main age periods of child development and their influence on the course of tumour processes.

**Content of the class.**

By definitions of Abrykosov and Strukov, **the tumor is** the reactive growth of the tissue, which is different from physiological growth; namely, it is a pathologic manifestation of growth and development of tissue, and of cells, which is caused by malignancy of their flow, disturbance of physiologic mechanisms, regulating the development of tissues, their structure and function.

**The real tumors have their peculiarities**, which differ them from the similar by external signs, new formations (tumor-like) namely:

1. With removal of the reason of tumor formation, its growth is not stopped.
2. Pathologic peculiarities of tumor cells and pathologically changed metabolism of substances inside them –lead to the cell's unlikeness and polymorphism and these signs are inherited by their ancestors. Many new peculiarities appear in them –the ability to germinate into other tissues and organs.

**The pathologic signs of tumor growth are:**

- atypicality of their multiplication – non-regulated and non-limited mitosis;
- atypicality of metabolism- in particular, oncoproteins' synthesis;
- antigenic atypicality –which means the simplification of antigen composition;
- morphological atypicality –cell and tissue atypicity (cataplasia);
- functional atypicality;
- physico-chemical atypicity-in particular the saturation of tumor cells of hydrogen is increased, and this facilitates the diffusion of their substrates' metabolism, and, along with this, the saturation by Calcium ions is decreased, what leads to worsening of inter- cell adhesion.

**The benign or mature tumors** consist of cells, by means of which one may determine, what tissue they originate from. They are called homological tumors.

**The malignant or immature tumors** consist of slightly or no differentiated cells, which loose similarity to tissue, they have been formed from. The less the tissue is differentiated, the more malignant is its course.

Children make more than 15 % among patients with oral-facial area neoplasia. The frequency of malignant neoplasm of maxillo-facial area in children grew from 5 to 16% (L.M.Kliachkina) and it makes, according to recent data-12 cases per 100 thousand of children. Unfortunately, this growth is being continued. In averaged, the malignant tumors of

head and neck make approximately 8% of all malignant tumors in child age (by data of oncologic institute in Paris, 1975), or 10% of all neoplasm of maxillo-facial area.

The necessity of knowledge of oncologic aspects of pedodontics-is stipulated by causes, independent from age, and also stipulated by peculiarities of children's organism development, namely:

1. The tumors of maxillo-facial area are located close to the brain and to main vessels and nerves of head and neck. The pointed out tumors may considerably worsen the process of food intake, breathing, eye functions, ear and nose functions, and also manifest visible cosmetic defects.

2. The age aspect means, that it is more difficult to determine in children, than in grown-ups, by way of morphologic investigation, whether the cells are regarded to no mature, non-differentiated tissues, where these are the cells of malignant tumor, and that is why, in child's age it almost impossible to establish exactly whether the tissue is benign or malignant (O.O.Kolesov, 1991). This is also a case of fact, that 70% of children with malignant tumors of maxillo-facial area attend doctors with tumor processes, which have started much earlier, and now being in such degree, that is almost impossible to cure.

**All tumors are classified** into benign and malignant.

**Benign tumors** grow slowly, as a rule, they are surrounded by capsule, and don't grow, but only move apart the neighboring tissues or organs. They don't form metastases and don't relapse after radical removal. But keep in mind, that benign tumors may press on the neighboring organs, causing disturbance of their function, atrophia; they may tighten vessels and nerves, with different consequences. Sometimes they may threaten the life of a child, disturbing lively important functions.

**The malignant tumors** of MFA are most often diagnosed in children 3-4 and 7-10 years old, 80% of them are sarcomas. Malignant tumors grow rapidly and don't have a capsule. They grow into other tissues and organs, ruining them. The cells of such tumors, growing into blood-carrying and lymphatic vessels, flowing with liquid stream, may be sometimes carried away to further located organs, causing the development of new tumors in them, called metastases. Such tumors cause disturbance of metabolism in the organism, its intoxication by products of life-activity, and at later stages of self decay-the self exhaustion (cohesion). Their infiltration growth hampers the determination of tumor borders. The infiltration growth leads to vessels destruction and bleedings, which sometimes may be mortal.

They are divided into groups, depending on their origin, from the certain tissue, or from the certain organ. These groups take into account the known morphologic types of neoplasm.

## **BENIGN and MALIGNANT**

Epithelial tumors

Tumors of soft tissues.

Tumors of bones and cartilage.

Tumors of lymphoid and blood-forming tissue.

Tumors of mixed genesis.

Secondary tumors.

Tumors, which are not classified.

Tumor-like conditions.

**Hemangioma** is the most common type of vascular anomaly (birthmark). It is a benign (noncancerous) tumor of the cells, called endothelial cells, that normally line the blood vessels. In hemangiomas, the endothelial cells multiply at an abnormally rapid rate.

Hemangioma may be:

- In the top skin layers (capillary hemangioma)
- Deeper in the skin (cavernous hemangioma)
- Branchy hemangioma
- Mixed hemangiomas

Infantile hemangiomas have a fairly predictable pattern of growth. Most appear during the first weeks of life and grow rapidly (called the proliferative phase) for 6 to 12 months. Then they begin a much slower process of shrinking, or regressing (called the involuting phase), which may take from one to about seven years. Finally, the tumor enters its final, shrunken state (called the involuted phase), after which it will never regrow. Tumor regression is complete in 50% of children by age 5 and in 70% of children by age 7. By the time a child reaches 10 to 12 years of age, involution of the tumor is always complete. Some residual fatty tissue or thin skin may remain after involution.

**Fibromas** are growths that form in a person's mouth in response to repeated injury, irritation or disease. These elevated areas of mostly scar tissue can appear anywhere inside the mouth, including on the tongue, lips, gums and inner cheeks. They can take months or even years to form. Fibromas typically appear as small areas of elevated tissue that are pink or white. When these scars are traumatized, they may appear reddish or blue. They tend to have a smooth surface and may be round, oval or elliptical in shape. They may have a stalk-like base or be fixed to the surface. The size of a fibroma can vary from a few millimeters to about 2 centimeters (1 inch). In some cases they feel firm and hard, but in other cases, they are soft, spongy and easily palpable. They are not typically painful but they may become annoying if not removed.

**Lipoma** is a benign tumor composed of fatty tissue. These are the most common form of soft tissue tumor. Lipomas are soft to the touch, usually movable, and are generally painless. Many lipomas are small (under one centimeter diameter) but can enlarge to sizes greater than six centimeters.

**Lymphangioma** is a rare, benign, congenital disorder in which a blockage in the lymphatic system causes fluid to accumulate in bubbles beneath the skin. These proliferations of lymph vessels may occur anywhere, but around 75% occur in the head and neck regions, or in the groin. Around 90% are either evident at birth or become evident before age two years. Since they have no chance of becoming malignant, lymphangiomas are usually treated for cosmetic reasons only.

The **cervical lymphoepithelial or branchial cleft cyst** is a developmental cyst that is usually present as a unilateral, soft-tissue fluctuant swelling that typically appears in the lateral aspect of the neck, anterior to the sternocleidomastoid muscle, and becomes clinically evident late in childhood or in early adulthood.

### Types

- First branchial cleft cysts typically originate in the angle of the mandible and extend to the external auditory canal. They are often associated with the the facial nerve
- Second branchial cleft cysts are most common. They are found along the anterior border of the sternocledomastoid, passes through the carotid bifurcation and into the tonsillar pillar
- Third branchial cleft cysts are rare and found in the lateral neck

The **midline (thyroglossal) cysts and ducts of the neck** belong to a developmental malformation of the branchial apparatus.



The congenital cysts and ducts of the neck are observed in 1 person on 3000 newborns. Clinically they are manifested at 4 till 7 years old or at 10-14 years that can be connected with hormonal changes in the child's organism. The primary ducts are connected with oss hyoideus and foramen cecum linguae (cecal foramen of tongue). Secondary ones are formed due to suppuration of midline cysts.

**Papilloma** refers to a benign epithelial tumor growing exophytically (outwardly projecting) in finger-like fronds. Two types of papilloma often associated with HPV are "squamous cell papilloma" and "transitional cell papilloma".

A **dermoid cyst** is a cystic teratoma that contains developmentally mature skin complete with hair follicles and sweat glands, sometimes clumps of long hair, and often pockets of sebum, blood, fat, bone, nails, teeth, eyes, cartilage, and thyroid tissue. Because it contains mature tissue, a dermoid cyst is almost always benign. The rare malignant dermoid cyst usually develops squamous cell carcinoma in adults; in infants and children it usually develops an endodermal sinus tumor.

An **epidermoid cyst** is a benign cyst usually found on the skin. The cyst develops out of ectodermal tissue. Histologically, it is made of a thin layer of squamous epithelium.

**Neurofibromatosis** is also known as **von Recklinghausen disease** is a genetically-inherited disorder in which the nerve tissue grows tumors (neurofibromas) that may be benign and may cause serious damage by compressing nerves and other tissues. The disorder can affect many neural crest cell-derived nerve tissues (e.g., Schwann cells, melanocytes and endoneurial fibroblasts). Cellular elements from these cell types proliferate excessively throughout the body, forming tumors; melanocytes also function abnormally in this disease, resulting in disordered skin pigmentation and café au lait spots. The tumors may cause bumps under the skin, colored spots, skeletal problems, pressure on spinal nerve roots, and other neurological problems

### **Comprehensive control:**

1. Rhabdomyoma: definition, clinical course, diagnosis, diff.diagnosis, treatment.
2. Lipoma: definition, clinical course, diagnosis, diff.diagnosis, treatment.
3. Myxoma: definition, clinical course, diagnosis, diff.diagnosis, treatment.
4. What are the main complains in children with benign tumors of maxillo-facial area?
5. Classification of hemangiomas.
6. Diagnosis, diff.diagnosis of vascular tumours.
7. Principles of surgical treatment of hemangiomas.
8. Sclerotic therapy. Indications.
9. Lymphangioma: definition, clinical course, diagnosis, diff.diagnosis, treatment.

### **Test control:**

1. Parents of 2 years old girl complain of bright red color formation of size 1 to 1.5 cm that is not elevated over the mucous level on the upper lip area. The neoplasm changes its color during pressing, paleness appears. Regional lymph nodes, clinical blood and urine tests are without pathological changes. Put the preliminary diagnosis?

- \*A. Capillary hemangioma
- B. Capillary lymphangioma
- C. Cavernous hemangioma

- D. Cavernous lymphangioma
- E. Pyogenic granuloma

2. The 3 month boy's mother complains of the presence of swelling of the left parotid area that is growing rapidly in her son. During examination of the left parotid area a rough surface with unclear borders of soft consistency was revealed. Neoplasm is painless during palpation. The skin over the swelling is not changed. Parotid salivary gland function is not affected. Cloudy yellowish liquid was received during puncture biopsy. Put the preliminary diagnosis.

- \*A. Lymphangioma of parotid area
- B. Hemangioma of the parotid area
- C. Retention cyst of the parotid gland
- D. Chronic parenchymatous parotitis
- E. Pseudoparotitis Herzenberg

3. Parents of 1.5 years old child referred to the clinic with complains of an enlargement of tongue, difficulties with food intake. Child suffers from birth. Objectively: general condition is without obvious pathology. Tongue is increased in size (macroglossia), mucous membrane is represented by the vesicle-like granulated growth. Tongue is thick, painless on palpation. What is the most correct diagnosis?

- \*A. Lymphangioma of the tongue
- B. Hemangioma of the tongue
- C. Fibroma of the tongue
- D. Cyst of the tongue
- E. Malignant tumor of the tongue

4. Mother of 3 months old girl complains of the presence of tissue deformation on the upper lip and left cheek area in her child. The cyanosis of the skin in this area is observed. Tumor increases in size. Objectively: facial asymmetry due to the presence of tumor of left cheek and upper lip area is revealed. The skin over deformation is cyanotic in color. Symptom of filling is positive. Select the most correct diagnosis

- \*A. Hemangioma
- B. Fibroma
- C. Cyst of the soft tissues
- D. Neurofibromatosis
- E. Cherubism

5. Parents of 11 months girl complain of the presence of a large neoplasm in the area of the chin and both submandibular areas of the child. Formation was detected at birth. The neoplasm grows slowly, but during acute respiratory viral disease, tumor increases in size in 2-3 times, and then gradually decreases. Objectively: soft tissue tumor without clear borders is revealed in both submandibular and submental areas. The neoplasm of paste-like consistency and painless during palpation is observed. The skin over the formation is not changed. Opening of the mouth is not limited. Tongue is increased in size. Enlarged papillae of the tongue contain of a clear yellow liquid. Provide the clinical diagnosis.

- \*A. Cystic form of lymphangioma
- B. Myoma
- C. Thyroglossal duct cyst
- D. Cavernous hemangioma
- E. Neurofibromatosis

6. Parents of a 6-year-old child complain of the presence of the tumor in the left parotid area, which gradually increased. The colour of the skin over the tumor is not changed. Tumor is not painful, but during putting the head down it increases in size and the skin becomes cyanotic. What disease can be predicted in child?

- \*A. Haemangioma
- B. Fibroma
- C. Ateroma
- D. Lymphangioma
- E. Cyst of parotid glandule

7. Mother of the 4-year-old child complains of the presence of neoplasm on the tongue, which slowly increases and does not hurt. During the examination on the tip of tongue the pathological neoplasm on a broad base was revealed. On its surface small thin fibers are visible. Neoplasm is painless, soft during palpation. What is preliminary diagnosis?

- \*A. Lymphangioma
- B. Lipoma
- C. Fibroma
- D. Haemangioma
- E. Papilloma

8. Mum of the 4-year-old child complains of a red dot spot on his face. It appeared a month ago and is growing. During the examination the pathological red spot of spidery form in the infraorbital area was revealed. During putting pressure the painting disappears in the centre of the spot. What is the preliminary diagnosis?

- \*A. Cavernous haemangioma
- B. Capillary haemangioma
- C. Vascular nevus
- D. Pigmented nevus
- E. Verrucose nevus

9. 1 month after injury of the mucosa of the lower lip of a 3-year-old child the tumor-like formation appeared of rounded, painless, soft, bluish-colored, 8 mm in diameter. Put the diagnosis:

- \*A. Lymphangioma of the lower lip
- B. Hemangioma of the lower lip
- C. Retention cysts of the minor salivary gland
- D. Papilloma of the lower lip
- E. Fibroma of the lower lip

10. One day ago, at home, a 6-year-old boy banged his forehead. A few hours later a tumor appeared in the right superciliary area. Objectively: the significant swelling of the forehead tissue that covers eyelid of the right eye. The skin over the tumor is cyanotic. The tumor is soft in consistency, the symptom of fluctuation exists. The general condition of the boy is not disturbed. Set the preliminary diagnosis.

- \*A. Hematoma of the right superciliary area
- B. Post-traumatic swelling of the right superciliary area
- C. Fracture of frontal bone
- D. Suppurative hematoma of the right superciliary area
- E. Inflammatory infiltrate of the right superciliary area

11. Parents of 11 months girl complain of the presence of a large neoplasm in the area of the chin and both submandibular areas of the child. Formation was detected at birth. The neoplasm grows slowly, but during acute respiratory viral disease, tumor increases in size in 2-3 times, and then gradually decreases. Objectively: soft tissue tumor without clear borders is revealed in both submandibular and submental areas. The neoplasm of paste-like consistency and painless during palpation is observed. The skin over the formation is not changed. Opening of the mouth is not limited. Tongue is increased in size. An enlarged papillae of the tongue contain of a clear yellow liquid. Provide the clinical diagnosis.

- \*A. Cystic form of lymphangioma
- B. Myoma
- C. Thyroglossal duct cyst
- D. Cavernous hemangioma
- E. Neurofibromatosis

12. The parents of 2 years old boy complain of an existence of brown color neoplasm on the left buccal area with irregular surface and wiry hair on it in their child. The neoplasm was detected immediately after childbirth and it is insignificantly growing within the child's growth. Put the diagnosis.

- \*A. Pigmented nevus
- B. Vascular nevus
- C. Kaposi sarcoma
- D. Neurofibromatosis of the face
- E. Melanoma of the cheek

13. The parents of a 3-year-old boy appealed to a dental surgeon with complaints of the presence of tumor in a superciliary area in their child. Objectively: in a right superciliary area there is a 2.3 cm tumor of the soft-elastic consistency, round in shape. A skin above it is slightly swollen and neither changed nor soldered. The puncture biopsy revealed a mass of whitish color. What is the most reliable diagnosis?

- \*A. Dermoid cyst of right superciliary area
- B. Cutaneous hernia
- C. Epidermoid cyst of right superciliary area
- D. Lymphangioma of the right superciliary area
- E. Hemangioma of the right superciliary area

14. The parents of 2 years old boy were referred to the dental hospital with the complains of the presence of the brown color hairy formation, with rough surface in a left buccal area in their child. The formation has been presented since childbirth. Its growth slightly increases with time. Put diagnosis.

- \*A. Pigmented nevus
- B. Vascular nevus
- C. Sarcoma Kaposi
- D. Neurofibromatosis of the face
- E. Melanoma of the buccal area

15. The patient of 8 years old was sent for the dental consultation due to the presence of the formation on the tongue. On the left side of the tongue, near the tip, there is a growth on a narrow base of pale pink color, without the infiltration of surrounding tissues, painless on palpation. Measuring of swelling is up to 0.8 cm. What is the most correct preliminary diagnosis?

- \*A. Papilloma of the tongue

- B. Fibroma of the tongue
- C. Cyst of the tongue
- D. Hemangioma of the tongue
- E. Lymphangioma of the tongue

16. During the examination of the 8 years old girl the neoplasm in the submental area with soft-elastic consistency was revealed. It is located in the middle line of the neck and is up to 2 cm in diameter. The neoplasm is a round-shaped with limited mobility (moves upwards during swallowing). Palpation is painless. Set the preliminary diagnosis:

- \*A. Thyroglossal cyst of the neck ( medial cyst)
- B. Dermoid cyst of the submental area
- C. Cyst of the sublingual salivary gland
- D. Chronic lymphadenitis of the submental area
- E. Cyst of submental salivary gland

17. During the examination of the 12 years old girl the neoplasm in the area of upper third of the front surface of the sternocleidomastoideus muscle was revealed. The tumour is with soft-elastic consistency, up to 3 cm in diameter, with limited mobility. Palpation is painless. The symptom of fluctuation is positive. Choose the method of treatment.

- \*A. Cystectomy
- B. Cystotomy
- C. Suturing of the tumour
- D. Punction of the tumour with sclerotic therapy
- E. Sclerotic therapy

18. During the examination of the 12 years old girl the neoplasm in the area of upper third of the front surface of the sternocleidomastoideus muscle was revealed. The tumour is with soft-elastic consistency, up to 3 cm in diameter, with limited mobility. Palpation is painless. The symptom of fluctuation is positive. Set the diagnosis:

- \*A. Lateral cyst of the neck
- B. Thyroglossal cyst of the neck
- C. Dermoid cyst of the neck
- D. Epidermoid cyst of the neck
- E. Lymphangioma of the neck area

19. During the examination of the 14 years old gboy the neoplasm in the area of the bridge of the nose was revealed. The tumour is with solid-elastic consistency, up to 1,8 cm in diameter and it appeared few months ago. Palpation is painless. The tumour is slightly soldered with skin and its mobility is limited. The child is somaticly healthy. Choose the adequate method of anesthesia during surgical treatment of the boy:

- \*A. Infiltrative anesthesia
- B. Intravenous anesthesia
- C. Infraorbital anesthesia
- D. Endotracheal anesthesia
- E. Conductive anesthesia

20. During the examination of the 12 years old girl the round-shaped neoplasm in the area of the forehead was revealed. The skin above the tumour is hyperemic. The neoplasm is with solid-elastic consistency, up to 1,8 cm in diameter, soldered with skin. Palpation is painful. The symptom of fluctuation is positive. The body temperature is risen. Set the diagnosis:

- \*A. Suppurated atheroma of the forehead

- B. Atheroma of the forehead
- C. Fibroma of the forehead
- D. Suppurated dermoid cyst of the forehead
- E. Abscess of the soft tissues of the forehead

**Recommended literature:**

1. Michael Miloro ,2004 London PETERSON'S PRINCIPLES OF ORAL AND MAXILLOFACIAL SURGERY Second Edition
2. Pediatric Oral and Maxillofacial Surgery Leonard B. Kaban, Maria J. Troulis, 2004

**Practical class 2.**

**Tumors verae and tumors-like neoplasms of salivary glands.**

**Osteogenic tumors of the bones of the maxillo-facial area (Giant-cell tumor of bone, Osteoma, Osteoid-osteoma). Odontogenic neoplasm of Jaws in Children (Ameloblastoma, Odontoma, Cementoma).**

*Teaching objective:* to familiarize students with clinical course, diagnosis, treatment of tumours and tumour-like neoplasms of the salivary glands and tumours of the bone of maxillo-facial area in children.

**Pre-study test questions:**

1. The difference between tumour and tumour-like neoplasm.
2. Anatomy of the salivary glands in children.

**Content of the class.**

**Parotid glands**

The parotid gland are a pair of major salivary glands wrapped around the mandibular ramus. It is one of a pair being the largest of the salivary glands, it secretes saliva to facilitate mastication and swallowing and to begin the digestion of starches. The secretion produced is mainly serous in nature and enters the oral cavity via the parotid duct or Stensen duct. It is

located posterior to the mandibular ramus and anterior to the mastoid process of temporal bone.

**Submandibular glands** The submandibular glands are a pair of major salivary glands located beneath the lower jaws, superior to the digastric muscles. The secretion produced is a mixture of both serous fluid and mucus, and enters the oral cavity via the submandibular duct or Wharton duct. Approximately 70% of saliva in the oral cavity is produced by the submandibular glands, even though they are much smaller than the parotid glands.

### **Sublingual glands**

The sublingual glands are a pair of major salivary glands located inferior to the tongue, anterior to the submandibular glands. The secretion produced is mainly mucus in nature, however it is categorized as a mixed gland. Unlike the other two major glands, the ductal system of the sublingual glands do not have intercalated ducts and usually do not have striated ducts either so they exit directly from 8-20 excretory ducts. Approximately 5% of saliva entering the oral cavity come from these glands.

### **Minor salivary glands**

There are 800-1000 minor salivary glands located throughout the oral cavity within the submucosa of the oral mucosa in the tissue of the buccal, labial, and lingual mucosa, the soft palate, the lateral parts of the hard palate, and the floor of the mouth or between muscle fibers of the tongue. They are 1-2mm in diameter and unlike the major glands, they are not encapsulated by connective tissue, only surrounded by it. The gland has usually a number of acini connected in a tiny lobule. A minor salivary gland may have a common excretory duct with another gland, or may have its own excretory duct. Their secretion is mainly mucous in nature (except for Von Ebner glands- see next section) and have many functions such as coating the oral cavity with saliva. Problems with dentures are sometimes associated with minor salivary glands if there is dry mouth present (see further discussion). The minor salivary glands are innervated by the seventh cranial or facial nerve.

### **Von Ebner glands**

Von Ebner glands are glands found in a trough circling the circumvallate papillae on the dorsal surface of the tongue near the sulcus terminalis. They secrete a purely serous fluid that begins lipid hydrolysis. They also facilitate the perception of taste through secretion of digestive enzymes and proteins.

**Ameloblastoma** is a rare, benign tumor of odontogenic epithelium (ameloblasts, or outside portion, of the teeth during development) much more commonly appearing in the mandible than the maxilla. While these tumors are rarely malignant or metastatic (that is, they rarely spread to other parts of the body), and progress slowly, the resulting lesions can cause severe abnormalities of the face and jaw. Additionally, because abnormal cell growth easily infiltrates and destroys surrounding bony tissues, wide surgical excision is required to treat this disorder. Further, dentists caution that wide surgical excision is not invasive enough to adequately treat this disorder.

There are three main clinical subtypes of ameloblastoma: unicystic, multicystic, peripheral. The peripheral subtype composes 2% of all ameloblastomas. Of all ameloblastomas in younger patients, unicystic ameloblastomas represent 6% of the cases. A fourth subtype, malignant, has been considered by some oncologic specialists, however, this

form of the tumor is rare and may be simply a manifestation of one of the three main subtypes.

**Central giant cell tumour** is a benign condition of the jaws. Central giant cell tumors are more common in the mandible and often crosses the midline. It is a benign intraosseous lesion found in the anterior of the maxilla and the mandible in younger people (before age 20). It is characterized by large lesions that expand the cortical plate and can reabsorb roots and move teeth. It is composed of multinucleated giant cells. It has a slight predilection for females. Radiographically it appears as multilocular radiolucencies of bone.

**Osteoma** is a benign bony outgrowth of membranous bones. They are found mostly on skull and facial bones. Soft tissue osteomas may occur in the head, eye, and tongue, or in the extremities. Osteomas are slow growing lesions that are normally completely asymptomatic. They only present if their location within the head and neck region is causing problems with breathing, vision, or hearing.

**Osteoid Osteoma** is a benign bone lesion with a nidus of less than 2 cm surrounded by a zone of reactive bone. This lesion accounts for approximately 10 % of benign bone tumors. The tumor occurs most frequently in the second decade and affects males twice as often as females. The proximal femur is the most common location followed by the tibia, posterior elements of the spine, and the humerus. Osteoid Osteoma is found in the diaphysis or the metaphysis of the proximal end of the bone more often than the distal end.

### **Comprehensive control**

1. Monomorphic adenoma: clinical course, diagnosis, treatment.
2. Pleomorphic adenoma: clinical course, diagnosis, treatment.
3. Retention cyst of the salivary gland: clinical course, diagnosis, treatment.
4. Hourglass- shaped cyst of salivary gland: clinical course, diagnosis, treatment.
5. Ranula: clinical course, diagnosis, treatment.
6. Odontoma: clinical course, diagnosis, treatment.
7. Ameloblastoma: clinical course, diagnosis, treatment.
8. Giant cell tumour: clinical course, diagnosis, treatment.
9. Osteoma: clinical course, diagnosis, treatment.
10. Osteoid-osteoma: clinical course, diagnosis, treatment.

### **Test- control:**

1. What tumours are referred to the epithelial growth?

- \*A. Adenoma
- B. Lymphangioma
- C. Fibroma
- D. Lipoma
- E. Hemangioma

2. Synonym of pleomorphic adenoma is:

- \*A. Mixed tumor
- B. Adenolymphoma
- C. Monomorphic adenoma
- D. Lipoma
- E. Basal cell carcinoma



3. Pleomorphic adenoma most often is observed in:

- \*A. Parotid area
- B. Sublingual area
- C. Submandibular area
- D. Minor salivary gland
- E. Sweat gland

4. Pleomorphic adenoma is:

- \*A. Covered by capsule but not all along
- B. Covered by evident capsule all along
- C. Not covered by capsule
- D. Covered by thin capsule
- E. Malignant tumour

5. Monomorphic adenoma consists of:

- \*A. Adenous (glandular) tissue
- B. Mesenchyme-like structure
- C. Adenous (glandular) and Mesenchyme-like structure
- D. Epithelium tissue
- E. Fibrous tissue

6. Pleomorphic adenoma consists of:

- \*A. Adenous (glandular) and mesenchyme-like structure
- B. Mesenchyme-like structure
- C. Adenous (glandular) tissue
- D. Epithelium tissue
- E. Mucus structure

7. What symptom can indicate for malignization of the pleomorphic adenoma?

- \*A. Rapid intensive growth of the tumour and limitation of mobility
- B. Slow growth of the tumour
- C. Painfulness of the tumour
- D. Mobility of the tumour nodule
- E. Throbbing pain

8. What treatment tactic should be chosen if the tumour is located in the deep part of the parotid gland?

- \*A. Total parotidectomy
- B. Partial parotidectomy
- C. Subtotal parotidectomy
- D. Enucleation of the tumour
- E. All tactics are incorrect

9. During management of subtotal parotidectomy the following treatment should be provided:

- \*A. External part of the parotid gland should be removed
- B. External and internal parts of the parotid gland should be removed
- C. Internal part of the parotid gland should be removed
- D. Tumour is removed with 1 cm of sound adjacent glandular tissue
- E. All parotid gland is removed

10. During management of partial parotidectomy the following treatment should be provided:

- \*A. Tumour is removed with 1 cm of sound adjacent parenchymatous glandular tissue
- B. External part of the parotid gland should be removed
- C. Internal part of the parotid gland should be removed
- D. All parotid gland is removed
- E. Internal and external parts of the gland should be removed

11. After the clinical and X-ray examination of a 15-year-old patient the osteoblastoclastoma of the lower jaw was diagnosed (a cystophorous form. The diagnosis is confirmed by the specific punctuate (a brown liquid). A tumor keeps outside a cortical plate which is thin. What method of treatment should be chosen in order to apply to this tumor?

- \*A. Exfoliation of the tumor simultaneously with a shell
- B. Cystectomy
- C. Curettage of the tumor within the limits of the healthy tissues
- D. Cystotomy
- E. Resection of the lower jaw with a bone plastic

12. A 12- year-old child is directed to a hospital with a suspicion of osteoblastoclastoma of the lower jaw. What of the transferred researches must be conducted for the confirmation of the clinical diagnosis?

- \*A. X-ray examination, puncture biopsy of tumor
- B. Microbiology research of puncture of the tumor
- C. Ultrasonic research of the lower jaw, cytology research of a tumor
- D. Thermovisiography research, Ultrasonic research of the lower jaw
- E. X-ray and ultrasonic research of the lower jaw

13. The parents of an 8-year-old girl appealed with complaints of the absence of the 11 tooth. During the roentgenologic examination there was revealed the shade of high intensity with clear hill's contours. It consists of the conglomerations of the tooth tissues. What is the most credible diagnosis?

- \*A. Odontoma
- B. Adamantinoma
- C. Odontogenic fibroma
- D. Follicle cyst
- E. Radix cyst

14. The parents of a 13-year-old child appealed with complaints about the absence of the 45 tooth. Objectively: a convexity in the lower jaw from a vestibular surface in the area of the absent the 45 tooth is present. The surface in this area is smooth, painless on palpation. On the X- ray a shade of high intensity with clear contours is observed. There are numerous tooth-like forms on a background shade. What is the most credible diagnosis?

- \*A. Odontoma of the lower jaw
- B. Ameloblastoma of the lower jaw
- C. Odontogenic fibroma of the lower jaw
- D. Follicular cyst of the lower jaw from the 45 tooth
- E. Radicular cyst of the lower jaw from the 45 tooth

15. Osteoblastoclastoma (cysts form) is diagnosed in a patient of 14 years old. The resorption of the bone tissue with the area of sclerosis around it was revealed on the X-ray. Multiple shallow cavities, horizontal resorption of dental roots in the tumorous area were present. What treatment is obvious to the patient?

- \*A. Surgical

- B. Chemotherapy
- C. Symptomatic
- D. Combined
- E. Radial therapy

16. An 11-year-old child is complaining of the painless tumor presence of the mandible on the right. During palpation of the body of the mandible on the right Dupuytren's symptom is marked. The X-ray shows right lower jaw bone defect with clear edges 3x4 cm, which has 45 tooth follicle inside. Temporary teeth are intact. What is the most likely diagnosis?

- \*A. Osteoblastoklastoma
- B. Cavernous haemangioma
- C. Radicular cyst
- D. Follicular cyst
- E. Adamantinoma (solid form)

17. Parents of the 7-year-old boy turned into a children's dental clinic with complains of the 11th tooth's absence. During the objective examination the increased alveolar bone in the projection of 11th, 12th teeth was revealed. On X-ray the multiple shadows of various sizes that have teeth-like shape were determined. Their density meets the hard tooth tissues. Clarify the diagnosis.

- \*A. Odontoma of the maxilla
- B. Follicular cyst of the upper jaw of the 11th tooth
- C. Cementoma of the maxilla
- D. Ameloblastoma of the upper jaw
- E. Odontogenic fibroma of the maxilla

18. Osteoma has such forms:

- \*A. Central and peripheral
- B. Intraossal and extraossal
- C. Solid and soft
- D. Osteoblastic and osteoclastic
- E. Intraossal and osteoclastic

19. Please, find out the correct X-ray picture of odontoma:

- \*A. Dense radiopaque area with clear margins that is surrounded by halo of radiolucent area of about 1 mm
- B. Round-shaped nidus of radiopacity with clear margins
- C. Round-shaped nidus of radiopacity with unclear margins
- D. Radiolucent nidus of bone destruction with radiopaque halo
- E. Radiolucent nidus of bone destruction with unclear margins

20. Please, find out the roentgenologic picture of osteoid-osteoma:

- \*A. Radiolucent nidus with unclear margins which is surrounded by radiodense rim
- B. Round-shaped radiopaque nidus with clear margins
- C. Radiopaque nidus with unclear margins
- D. Radiopaque nidus with clear margins which is surrounded by sclerotic rim
- E. Radiopaque nidus with unclear margins with hyperostosis

**Recommended literature:**

3. Michael Miloro ,2004 London PETERSON'S PRINCIPLES OF ORAL AND MAXILLOFACIAL SURGERY Second Edition
4. Pediatric Oral and Maxillofacial Surgery Leonard B. Kaban, Maria J. Troulis, 2004

### Practical class 3

**Tumor- like neoplasm of the jaw – Cysts.**

**Tumor -like neoplasms of Jaws: Fibro-osseous Dysplasia, Ordinary congenital epulis. Clinical features, diagnosis, diff. diagnosis of fibro-osseous dysplasia. Roentgenological pictures of fibrous dysplasia. Clinical features and treatment of Cherubism, McCune–Albright syndrome. Ordinary congenital epulis: clinic, diagnosis, diff. diagnosis, treatment.**

*Teaching objective:* to familiarize students with clinical course, diagnosis, treatment of tumour-like neoplasm of the jaw and with the tumor-like neoplasm of the jaw in children.

#### Pre-study test questions:

1. The difference between tumour and tumour-like neoplasm.
2. Classification of tumor-like neoplasm of the jaw.

#### Content of the class.

A cyst can be defined as a benign pathologic cavity within bone or in soft tissues, generally formed by a connective tissue wall. The cavity, within the oral regions, is almost always lined by epithelium. Some cyst-like lesions, without epithelial lining, also can be seen in the maxillo-facial regions. The cyst's lumen usually contains fluids, keratin or cellular debris.

#### **Radicular cyst** (Periapical cyst, apical cyst)

The most frequent cyst of the teeth bearing areas is the radicular, also called periapical or apical cyst. Around 60% of all jaw cysts are radicular or residual cysts. Radicular cysts can occur in the periapical area of any teeth, at any age but are seldom seen associated with the primary dentition. This cyst is classified as inflammatory, because in the majority of cases it is a consequence to pulpal necrosis following caries, with an associated periapical inflammatory response. Other causes include any event that may conduce to pulpal necrosis such as tooth fracture and improper restorations, among others. The first line of defense to pulpal necrosis in the periapical area is the formation of a granuloma. A granuloma is a highly vascularized tissue containing a profuse infiltrate of immunological competent cells, lymphocytes, macrophages, plasma cells, etc.

A **dentigerous cyst** or **follicular cyst** is an odontogenic cyst - thought to be of developmental origin - associated with the crown of an unerupted (or partially erupted) tooth. The cyst cavity is lined by epithelial cells derived from the reduced enamel epithelium of the tooth forming organ. Regarding its pathogenesis, it has been suggested that the pressure exerted by an

erupting tooth on the follicle may obstruct venous flow inducing accumulation of exudate between the reduced enamel epithelium and the tooth crown.

In addition to the developmental origin, some authors have suggested that periapical inflammation of non-vital deciduous teeth in proximity to the follicles of unerupted permanent successors may be a factor for triggering this type of cyst formation.

### **Residual cyst**

A residual cyst arises as a consequence of an improper surgical elimination of a radicular cyst. Its clinical and histological characteristics are identical to those of a radicular cyst. Radiologically it will be seen as a radiolucency of variable size at the site of a previous tooth extraction. Large residual cysts may be treated by marsupialization.

### **Paradental cyst**

The paradental cyst is an inflammatory cyst which develops on the lateral surface of a tooth root. Histologically the paradental cyst can not be differentiated from a radicular cyst. Some authors refer to this cyst as an inflammatory periodontal cyst or collateral cyst. This cyst is of rare occurrence and must be radiographically differentiated from the lateral periodontal cyst. It is treated by surgical ablation and does not have a tendency to recur.

**Fibrous Dysplasia** is an uncommon benign fibro-osseous lesion disease, of unknown aetiology. It causes bone thinning and growths or lesions in one or more bones, and leads to bone weakness and scar formation within the bones. These lesions are tumor-like growths that consist of replacement of the medullary bone with fibrous tissue, causing the expansion and weakening of the areas of bone involved. The lesions can cause externally visible deformities. Fibrous dysplasia usually occurs in children ages 3 to 15, but it sometimes is not diagnosed until adulthood. It is found equally between males and females.

**Cherubism (familial fibrous dysplasia)** is a rare genetic disorder (an autosomal dominant trait) characterized by abnormal bone tissue in the lower part of the face. Beginning in early childhood, both the mandible and the maxilla become enlarged as bone is replaced by fibrous tissue that is less dense, leading to swollen looking cheeks. Enlargement of the jaw usually continues throughout childhood and stabilizes during puberty.

The incidence of cherubism is unknown. At least 250 cases have been reported worldwide. It presents particularly in males, usually after the age of 4-5 years.

Mutations in the SH3BP2 gene have been identified in about 80 percent of people with cherubism.

**Fibro-osseous Dysplasia** is a developmental, non familial, benign anomaly of bone development occurring in single or multiple bones, characterised by the replacement of normal bone by fibro-osseous tissue.

The etiology is unknown. Could be due to the chronic inflammation process, endocrine disturbances or trauma. Begins at the early childhood and clinically manifestates at 20-30 years.

**McCune–Albright syndrome** is a genetic disorder of bones, skin pigmentation and hormonal problems along with premature puberty. McCune–Albright syndrome is suspected when two of the three following features are present:

- (autonomous) endocrine hyperfunction such as precocious puberty
- Polyostotic fibrous dysplasia

- Unilateral Café-au-lait spots

**Comprehensive control**

1. Paradental cyst: clinical course, diagnosis, treatment.
2. Radicular cyst: clinical course, diagnosis, treatment.
3. Follicular cyst: clinical course, diagnosis, treatment.
4. Residual cyst: clinical course, diagnosis, treatment.
5. Fissural cyst: clinical course, diagnosis, treatment
6. Cherubism: clinical course, diagnosis, treatment.
7. McCune-Albright syndrome: clinical course, diagnosis, treatment.
8. Fibro-osseous Dysplasia: clinical course, diagnosis, treatment.
9. Fibrous Dysplasia: clinical course, diagnosis, treatment.

**Test-control:**

1. Put the definition of the cyst:
  - \*A. Tumour-like disease
  - B. Connective tissue tumour
  - C. Epithelial tumour
  - D. Tumour from tooth formative tissue
  - E. Vascular tumour-like disease
2. What is the definition of the pseudocyst?
  - \*A. The cyst with lack of epithelial cells
  - B. The cyst with multilayered unceratinized epithelium
  - C. The cyst with multilayered ceratinized epithelium
  - D. The cyst with cuboidal epithelium
  - E. The cyst with squamous epithelium
3. What cyst of the jaw doesn't belong to odontogenic cysts?
  - \*A. Nasopalatine cyst
  - B. Radicular cyst
  - C. Follicular cyst
  - D. Epidermoid cyst
  - E. Paradental cyst
4. What kind of cyst can be located in the apical area?
  - \*A. Radicular
  - B. Follicular
  - C. Epidermoid
  - D. Paradental
  - E. Dermoid
5. Is cholesterol always observed in the radicular cyst cavity?
  - \*A. Yes, always
  - B. Sometimes it is observed
  - C. No, never
  - D. It is not the main characteristic feature of the radicular cyst
  - E. Could be present, not always

6. The symptom of paresthesia of the lip is observed due to radicular cyst's growing on:
- \*A. The lower jaw only
  - B. The upper jaw
  - C. The upper and lower jaw
  - D. The symptom is never observed with the cyst growing
  - E. The frontal area of the upper jaw
7. The deformation of the lower jaw from the lingual side can be observed due to cyst presence on:
- \*A. Second, third molar area
  - B. Frontal area
  - C. Bicuspid area
  - D. Canine area
  - E. First molar area
8. Put the definition of convergence:
- \*A. Approximation of the crowns of the teeth
  - B. Disapproximation of the crowns of the teeth
  - C. Approximation of the roots of the teeth
  - D. Disapproximation of the roots of the tooth
  - E. Root resorption
9. Put the definition of the divergence:
- \*A. Disapproximation of the roots of the teeth
  - B. Approximation of the roots of the teeth
  - C. Approximation of the teeth crowns
  - D. Inclination of the tooth crown
  - E. Resorption of the root
10. Supuration of the radicular cyst never leads to:
- \*A. Frontitis
  - B. Sinusitis
  - C. Osteomyelitis
  - D. Abscess
  - E. Periostitis
11. Put the definition of the osteodysplasy:
- \*A. An abnormality of development of bone tissue, due to restriction, perversion or arresting of osteogenesis on the proper stage of embryonic or postnatal developmental stage
  - B. Pathologic process with functional and structural abnormalities of different parts of osseous system due to disturbances of trophic of osseous tissue
  - C. Abnormalities of development of the osseous system
  - D. Abnormalities of development of the osseous system after trauma of the bones
  - E. All answers are correct
12. Put the definition of the osteodystrophy:
- \*A. Pathologic process with functional and structural abnormalities of different parts of osseous system due to disturbances of trophic function of osseous tissue
  - B. Abnormalities of development of the osseous system
  - C. Abnormalities of development of the osseous system after trauma of the bones

- D. An abnormality of development of bone tissue, due to restriction, perversion or arresting of osteogenesis on the proper stage of embryonic or postnatal developmental stage  
E. All answers are correct

13. Osteogenesis process which is observed in osteodysplasy can be damaged on the following its stage:

- \*A. Fibrous, cartilage, osteoid stages  
B. Fibrous stage  
C. Cartilage stage  
D. Osteoid stage  
E. There are no correct answers

14. Put the definition of Cherubism:

- \*A. Fibrous dysplasy of the lower jaw in the areas of the angles with genetic character  
B. Systemic disease with polyossal bone involvement with thickening of zygomatic bones and lower jaw in the mental area and depression of the bridge of the nose  
C. Fibro-Osseous dysplasy and hyperpigmentation of the skin and premature puberty  
D. Abnormality of bone development of the skeleton  
E. Osseous dystrophy of the upper jaw

15. Put the definition of McCune-Albright syndrome:

- \*A. Fibro-Osseous dysplasy and hyperpigmentation of the skin and premature puberty  
B. Abnormality of bone development of the skeleton  
C. Osseous dystrophy of the upper jaw  
D. Fibrous dysplasy of the lower jaw in the area of the angles with genetic character  
E. Systemic disease with polyossal bone involvement with thickening of zygomatic bones and lower jaw in the mental area and depression of the bridge of the nose

16. What treatment tactic should be chosen in case of Cherubism?

- \*A. No treatment  
B. Surgical treatment  
C. Conservative treatment  
D. Conservative-surgical treatment  
E. Criodestruction

17. The deformation of the face in patients with Cherubism can show the following changes with time:

- \*A. Decreases  
B. Increases  
C. Without any changes  
D. Periods of decrease are changed by increased periods  
E. No correct answers

18. Refer the epulis to the correct group of the diseases:

- \*A. Tumour-like neoplasm  
B. Benign tumor  
C. Malignant tumor  
D. Inflammatory disease of periodont  
E. Cyst of the jaw

19. What is the etiology of the epulis appearance?



- \*A. Trauma of the periodont due to overhanging fillings, absence of the contact point between the teeth, abnormal localization of the tooth in the dental arch etc
- B. Inflammation of the periodont on the apex area of the tooth
- C. Innate malformation of the periodont
- D. Vascular abnormality of periodontal tissue
- E. Idiopathic etiology

20. Epulis has the following forms:

- \*A. Fibrous, angiomatous
- B. Hypertrophic, angiomatous
- C. Fibrous, hypertrophic
- D. Cystic
- E. Sclerotic, angiomatous

**Recommended literature:**

1. Michael Miloro ,2004 London PETERSON'S PRINCIPLES OF ORAL AND MAXILLOFACIAL SURGERY Second Edition
2. Pediatric Oral and Maxillofacial Surgery Leonard B. Kaban, Maria J. Troulis, 2004

**Practical class 4**

**Malignant Tumors of Oral- Facial Area in Children.**

*Teaching objective:* to familiarize students with classification, clinical course, diagnosis, treatment of malignant tumors of the oral-facial area in children.

**Pre-study test questions:**

1. The difference between benign and malignant tumours of the oral-facial area in children.
2. Classification of malignant tumors of the jaw.

Content of the class.

**The malignant or no mature tumors** consist of slightly or no differentiated cells, which loose similarity to tissue, they have been formed from. The less the tissue is differentiated, the more malignant is its course.

Children make more than 15 % among patients with oral-facial area neoplasia. The frequency of malignant neoplasm of maxillo-facial area in children grew from 5 to 16% (L.M.Kliachkina) and it makes, according to recent data-12 cases per 100 thousand of children. Unfortunately, this growth is being continued. In averaged, the malignant tumors of head and neck make approximately 8% of all malignant tumors in child age (by data of oncologic institute in Paris, 1975), or 10% of all neoplasm of maxillo-facial area.

**The malignant tumors** of MFA are most often diagnosed in children 3-4 and 7-10 years old, 80% of them are sarcomas. Malignant tumors grow rapidly and don't have a capsule. They grow into other tissues and organs, ruining them. The cells of such tumors, growing into blood-carrying and lymphatic vessels, flowing with liquid stream, may be sometimes carried away to further located organs, causing the development of new tumors in them, called metastases. Such tumors cause disturbance of metabolism in the organism, its intoxication by products of life-activity, and at later stages of self decay-the self exhaustion (cohesion). Their infiltration growth hampers the determination of tumor borders. The infiltration growth leads to vessels destruction and bleedings, which sometimes may be mortal.

To make a correct diagnosis and for optimal organization of medical-prophylactic work concerning oncologic diseases of maxillo-facial area in children the doctors must know how to classify these diseases.

**The International Histological Classification** of the head and neck tumors, accepted by IOHP, looks in the following way:

1. Skin tumors
2. Tumors and tumor-like neoplasm of the mouth cavity and pharynx, formed of many-layer flat epithelium
3. Salivary glands tumors and tumor-like neoplasm
4. Soft tissue tumors
5. Primary bone tumors and tumor-like neoplasm
6. Odontogenic tumors, tumor-like neoplasm and cysts of the jaw bones.

Three signs of anatomic spreading of neoplasm are put into the basis of International classification: spread of primary focus (T04-tumor); regional metastasing (N0x-bundle); remote metastasing (N0x-metastas).

Among **malignant tumors of maxillo-facial area in children** there are:

- osteogenic sarcoma
- fibrosarcoma
- Uing sarcoma
- reticular sarcoma
- lymphogranulomatosis
- lymphosarcoma.

The doctors also observe the cancerogenic injuries of different localization: of lips, cheeks, tongue, jaw bones. The malignant tumors in children are prevailingly primary tumors of connective-tissue origin: fibrosarcoma, angiosarcoma and reticulosarcoma.

All malignant tumors must be treated at the in-patient department. The treatment is carried out according to previously composed plan, which follows the sequence of medicinal measures, their durability, a number of seances, dosage and so on.

In surgical treatment on neoplasm in children a doctor must follow such 2 conditions:

1. Radicality of an operation, because a not complete extraction of malignant and benign tumors leads to speeding of their growth or to recurrency, in which the possibilities of further radical treatment are worsened;
2. Absolute necessity of hystologic investigation of all extracted tumors, even if according to their clinics, macro- and morphologically they don't case any doubts of their benignity.

It's necessary to follow the principles of antiblastics and ablastics.

**Ablastics**-is the prevention of dessimination of tumor cells by way of scaree intrussion on the cell itself ( to avoid traumatizing of the cell, cuttings, pricks) and on surrounding tissues-to prevent the injury of lymphatic ducts, a doctor must protect the operational field, passing from tumorous tissues on surrounding healthy ones, to wash hands; to change gloves and instruments, operational gawn.

**Antiblastics**-a complex of measures, directed to ruin tumorous cells, which may penetrate into the operational wound, treating it by alcohol (spirit), iodine, applying an electric knife; diathermocoagulation or criosurgical instruments.

**The indications for therapy by X-rays or to distant  $\gamma$ -therapy** in children are:

- technical impossibility of radical surgical intervention;
- presence of tumors, disposed to postoperational recurrences;
- possibility to cure the tumors without surgical intervention ( with a necessary confirmation of the diagnosis by biopsy methods).

The following preparations are applied for **chemiotherapy**: antimetabolites, alkilous preparations, antitumor antibiotics, hormonal means and phytopreparations (e.g. fitohematoglutins, which assists to transformation of neutral lymphocytes into killer-cells). Gen-engineering and antisenstherapy are used, that is the influence on a concrete gen by way of syntesis inhibition of the appropriate protein.

At present doctors perform a row of reconstructive operations on lower jaw( mandible). As a rule, the resection of mandible in case of tumor leads to formation of partial or complete defect and that is why it is accompanied by primary or remote bone plastics. In the latter case a postoperational orthodontic treatment is carried out. It's rather important, that the head of a joint is preserved during resection and to preserve the function of a joint.

In all cases of surgical intervention on upper jaw with further defects the children 2-3 years old must be made dentures 2-3 weeks after operation. The child is discharged from the hospital to be watched by the local orthodontist.

In treatment of malignant tumors the main role belongs to surgical interventions. If to take a group of Yuing sarcomas, and reticular cyst the chemio- and ray therapy may be appropriate.

After a course of treatment at the oncologic in-patient department the children with malignant neoplasms must be constantly examined by dispensary oncologists and dentists. This may help to prevent the progress of a disease, prolong the remission of the disease and a patient's life. The task of postoperational dispensary observation is the control of possibility of recurrence, renewal of anatomical form, and a disturbed function , ensuring of correct growth and development of jaw-facial bones. That's why the dispensary care of the patient includes examinations of such specialists as: an orthodontist, pediatrician., logopedist and otolaryngologist.

The clinical, roengenological and hematological control in process of dispensary observation allows to timely reveal the recurrences or the progress of tumor process and to carry out the appropriate preventive therapy, to direct a child to onco-clinics. The repeated courses of therapy by cytostatics, scarcing diet, the all-round strengthening therapy and other

recommendations of oncologists are carried out and rendered by place of living of a patient. The dispensarised child at the onset of any respiratory infection, acuteness of periostitis, lymphadenitis, or a tonsilitis must be examined and cured with a special care, as these illnesses may be a result of a main oncopathology.

When the children become 18 years old, they pass to the analogical registration of grown-up persons.

**Comprehensive control**

1. Clinic and modern diagnosis of malignant tumors of jaws in children.
2. Types of sarcomas, their clinic, treatment.

**Test control:**

1. Spicules are the distinguishing feature of the next tumour:

- \*A. Osteosarcoma
- B. Osteoblastoma
- C. Fibrosteoma
- D. Osteoid-osteoma
- E. Osteoma

2. What treatment should be provided for the patients with osteosarcoma?

- \*A. Resection of the jaw
- B. Curettage of the pathologic nidus
- C. Resection and curettage of the pathologic nidus
- D. Radiotherapy
- E. Palliative treatment

3. During palpation osteosarcoma is:

- \*A. Painfull
- B. Painless
- C. Fluctuation is present
- D. Eggshell cracking symptom
- E. Nontender

4. Set the definition of malignant tumour:

- \*A. Is a broad group of diseases involving pathological unregulated cell growth
- B. Overgrowing of the cells that lacks the ability to invade neighboring tissue or metastasize
- C. Inflammation of the cells
- D. Pathological unregulated cell growth which never metastasize
- E. Pathological unregulated cell growth which never penetrates into adjacent sound tissues

5. What are the main reasons which can lead to the malignant tumour development?

- \*A. All answers are correct
- B. Chemical
- C. Biological
- D. Physical
- E. Mechanical trauma

6. What are the main distinguishing features of malignant tumor:

- \*A. All answers are correct
- B. Infiltrative growth

- C. Metastasis
- D. Recurrence
- E. Cachexy

7. What is the distinguishing feature of benign tumour?

- \*A. Resistance to radiotherapy and chemotherapy
- B. Infiltrative growth
- C. Quick growth
- D. Metastasis
- E. Cachexy

8. What is the distinguishing feature of malignant tumour?

- \*A. Cellular polymorphism
- B. Expansive growth
- C. Slow growth
- D. Clear margins on an X-ray
- E. Hyperplasia and dystrophy

9. What benign neoplasm does demonstrate an infiltrative growth?

- \*A. Hemangioma
- B. Lipoma
- C. Mixoma
- D. Fibroma
- E. Osteoma

10. What disease is characterized by cachexy, recurrence, immunodepression and infiltrative growth?

- \*A. Malignant tumour
- B. Tumor-like disease
- C. Benign tumour
- D. Inflammation
- E. Innate malformation

11. What disease is characterized by unclear margins on X-ray, presence of spicules and osteolysis?

- \*A. Malignant tumour
- B. Benign tumour
- C. Cysts
- D. Epulis
- E. Tumour-like disease

12. Systemic manifestations (paraneoplastic syndrome) are distinguished for:

- \*A. Malignant tumour
- B. Benign tumour
- C. Tumour-like neoplasm
- D. Cysts
- E. Osteomyelitis

13. Systemic vasculitis, hematological derangements, metabolic disorders, suppression of immune system, neuropathy, skin manifestation are distinguished for:

- \*A. Paraneoplastic syndrome

- B. Cachexy
- C. Metastasis
- D. Benign tumour
- E. All answers are incorrect

14. Put the definition of excochleation:

- \*A. Removal of the contents of a cavity by scraping or curetting within sound tissues
- B. Resection of the jaw within sound tissues
- C. Partial resection of the jaw
- D. Cystectomy
- E. Cystotomy

15. Describe the method of incisional biopsy:

- \*A. Biopsy of a selected portion of a lesion
- B. Biopsy in which tissue is obtained by puncture of a tumor
- C. Biopsy of tissue removed by surgical cutting
- D. Biopsy in which tissue is obtained by a punch
- E. Biopsy in which tissue is obtained by application of suction through a needle attached to a syringe

16. Describe the method of excisional biopsy:

- \*A. Biopsy of tissue removed by surgical cutting
- B. Biopsy in which tissue is obtained by a punch
- C. Biopsy in which tissue is obtained by application of suction through a needle attached to a syringe
- D. Biopsy in which tissue is obtained by puncture of a tumor
- E. Biopsy of a selected portion of a lesion

17. Describe the method of aspiration biopsy:

- \*A. Biopsy in which tissue is obtained by application of suction through a needle attached to a syringe
- B. Biopsy of tissue removed by surgical cutting
- C. Biopsy in which tissue is obtained by a punch
- D. Biopsy in which tissue is obtained by puncture of a tumor
- E. Biopsy of a selected portion of a lesion

18. What additional diagnosis procedure must be performed before resection of the jaw due to neoplasm?

- \*A. Pathohistologic verification of the diagnosis (biopsy)
- B. X-ray
- C. MRI
- D. CT Scan
- E. Blood test

19. Put the definition of ablative principle of surgery which is used for malignant tumour treatment:

- \*A. Principle in surgery which prevents the recurrence and metastasis of malignant tumors by removing the tumor focus, along with the lymph vessels and the regional lymph nodes within the healthy tissue without touching the affected tissues
- B. Set of measures that are used for wound cleaning from tumor cells remaining after removal of the tumor, including electrocoagulation, the use of drugs, etc

- C. Electrocoagulation of the vessels in the wound
- D. Antibiotic therapy after surgery
- E. Radiotherapy

20. Malignant neoplasm should be differentiated with the next processes:

- \*A. All answers are correct
- B. Benign tumours
- C. Chronic productive osteomyelitis
- D. Nonodontogenic periostitis
- E. Precancerous processes

### **Practical class 5.**

**Diagnostic criteria of the benign tumors and tumor-like neoplasms of the maxilla-facial area in children. Principles of the doctor's tactics and rehabilitation on the different stages of treatment.**

*Teaching objective:* to familiarize students with the clinical course, diagnosis and peculiarities of treatment and rehabilitation of the patients with benign tumors and tumor-like neoplasm of the MFA in children.

**Pre-study questions:**

1. Differences between benign and malignant tumors of the MFA.
2. Differences between benign and tumor-like neoplasm of MFA in children.

**Content of the practical class:**

**The benign or mature tumors** consist of cells, by means of which one may determine, what tissue they originate from. They are called homologous tumors.

**The malignant or immature tumors** consist of slightly or no differentiated cells, which loose similarity to tissue, they have been formed from. The less the tissue is differentiated, the more malignant is its course.

Children make more than 15 % among patients with oral-facial area neoplasia. The frequency of malignant neoplasm of maxillo-facial area in children grew from 5 to 16% (L.M.Kliachkina) and it makes, according to recent data-12 cases per 100 thousand of children. Unfortunately, this growth is being continued. In averaged, the malignant tumors of head and neck make approximately 8% of all malignant tumors in child age (by data of oncologic institute in Paris, 1975), or 10% of all neoplasm of maxillo-facial area.

The necessity of knowledge of oncologic aspects of pedodontics-is stipulated by causes, independent from age, and also stipulated by peculiarities of children' organism development, namely:

1. The tumors of maxillo-facial area are located close to the brain and to main vessels and nerves of head and neck. The pointed out tumors may considerably worsen the process of food intake, breathing, eye functions, ear and nose functions, and also manifest visible cosmetic defects.
2. The age aspect means, that it is more difficult to determine in children, than in grown-ups, by way of morphologic investigation, whether the cells are regarded to no mature, non-

differentiated tissues, where these are the cells of malignant tumor, and that is why, in child's age it almost impossible to establish exactly whether the tissue is benign or malignant (O.O.Kolesov,1991). This is also a case of fact, that 70% of children with malignant tumors of maxillo-facial area attend doctors with tumor processes, which have started much earlier, and now being in such degree, that is almost impossible to cure.

Tumor lesions vary in origin and may represent:

1. Embryonic development defect, disturbance of laying and forming of organs and tissues (vascular anomalies and malformations, lymphangioma, hamartoma, branchial and dermoid cysts, fibrous osteodysplazy, follicular cysts, etc.).
2. The manifestation of hereditary syndromes (neurofibromatosis, cherubism etc.).
3. The manifestation of systemic diseases (Sjogren's syndrome, gingival fibromatosis with hormonal disorders, parathyroid osteodystrophy, Paget's disease)
4. Outcome of acute or chronic injury (traumatic neuroma, simple or traumatic bone cyst, fibrous proliferation and papillomatosis of the oral mucosa)
5. Reactive hyperplasia in chronic inflammation (pyogenic granuloma, radicular cyst, tumor Kuttner)
6. Violation of outflow (retention) of secret of exocrine glands (salivary glands retention cysts)
7. Tumor-like lesions with unknown genesis (aneurismal bone cyst)

Another principle, which is based on the classification of tumors, is their histological structure (the ratio of stroma and parenchyma, cell shape and size, etc.). This criterion is often a key to identify a particular nosology, especially when histogenesis and origin of tumors is not fully understood.

### **Comprehensive control**

1. Clinic and modern diagnosis of benign tumors and tumor-like neoplasms in children.
2. Etiology, clinic, treatment.

### **Test control:**

1. The child was born with a small capillary haemangioma on the cheek, and after treatment in place of the tumor the slightly noticeable cosmetic scar of the irregular shape was present. Which method of treatment was used?

- \*A. Excision
- B. Cryodestruction with carbonic acid
- C. Diathermocoagulation
- D. Sclerotherapy of the tumor
- E. Mechanical destruction

2. What type of neoplasm of blood vessels can be treated by dermabrasion and cryodestruction?

- \*A. Capillary hemangioma
- B. Capillary lymphangioma
- C. Cystic lymphangioma(hygroma)
- D. Mixed hemangioma
- E. Cavernous hemangioma



3. What medical solution is used for sclerotic therapy during the management of hemangioma?

- \*A. All answers are correct
- B. Alcohol, novocaine, distilled water
- C. Quinine-urethane solution
- D. Calcium chloride
- E. Prednisolone solution locally

4. What method of treatment is used for management of lipoma?

- \*A. Radical surgical excision
- B. Chemiotherapy
- C. Cryotherapy
- D. Sclerotic therapy
- E. Diathermocoagulation

5. Parents of 2 months old girl turned to the surgent with complaints on the presence of tiny red spot on the skin of the hairy part of the neck in their daughter. The diagnosis of capillary hemangioma was set. What should be the first doctor's tactic in this case?

- \*A. Conservative treatment (expectant management)till the age of 1,5-2 years
- B. Surgical excision
- C. Sclerotic therapy
- D. Hormonal therapy
- E. Laser therapy

6. In what clinical cases the method of primary embolisation of main vessels as preparation for the following surgical intervention is used?

- \*A. Cavernous and mixed hemangioma
- B. Lipoma
- C. Cavernous lymphangioma
- D. Myoma
- E. Dermoid cyst

7. What method of treatment should be chosen for management of capillary lymphangioma of the tongue?

- \*A. Wedge-like resection of the tongue
- B. Sclerotherapy of the tongue
- C. Conservative treatment
- D. Laser therapy
- E. Combined methods of treatment

8. What method of treatment is preferable for the management of "Vine spot" (nevus flammeus)in children?

- \*A. Laser therapy
- B. Surgical excision

- C. Conservative treatment
- D. Sclerotherapy
- E. Dermabrasion

9. For the diagnosis of large-sized and deep-localized hemangiomae the informative method of diagnosis is:

- \*A. All answers are correct
- B. CT scan
- C. MRI
- D. Ultrasound diagnosis
- E. Doppler echography

10. The symptom of "filling and devastation" is common for the next pathology:

- \*A. Cavernous hemangioma
- B. Myoma
- C. Pigmented nevus
- D. Cavernous lymphangioma
- E. Capillary hemangioma

11. During the fine-needle aspiration biopsy of neoplasm of soft tissue of the left submandibular area the sticky bright-yellowish liquid is obtained. What pathology can be suspected after this examination?

- \*A. Lymphangioma
- B. Hemangioma
- C. Lipoma
- D. Epidermoid cyst
- E. Dermoid cyst

12. In what clinical cases of hemangioma's treatment the systemic hormonal and interferon therapy is prescribed?

- \*A. When surgical or sclerotic treatment is not available and rapid growth of tumor is observed
- B. Before surgical therapy
- C. In cases of small-sized hemangioma
- D. As the first stage of sclerotic therapy
- E. All answers are correct

13. During the examination of the 12 years old girl the neoplasm in the area of upper third of the front surface of the sternocleidomastoideus muscle was revealed. The tumour is with soft-elastic consistency, up to 3 cm in diameter, with limited mobility. Palpation is painless. The symptom of fluctuation is positive. Choose the method of treatment.

- \*A. Cystectomy
- B. Cystotomy
- C. Suturing of the tumour

D. Punction of the tumour with sclerotic therapy

E. Sclerotic therapy

14. The parents of 2 years old girl complain of the presence of painless deformation of the soft tissues of the temporal, parotid and buccal areas of the face on the left side in their daughter. The tumour has been represented since childbirth. The soft-tissue deformation does not differ from adjacent normal tissues by structure and color. There is a deformation of the upper alveolar process and its enlargement on the left side. The light brown spots of inside surface of the palms are present. Eosinophilia in the blood test is present. What tactic of treatment should be chosen?

\*A. Multistage surgical treatment with interdisciplinary approach

B. Sclerotic therapy before surgical intervention

C. Method of expectation and dispanserisation of the patient

D. Suturing of the tumor

E. X-Ray therapy

15. What treatment tactic should be chosen if the tumour is located in the deep part of the parotid gland?

\*A. Total parotidectomy

B. Partial parotidectomy

C. Subtotal parotidectomy

D. Enucleation of the tumour

E. All tactics are incorrect

16. What is the content of the ranula?

\*A. Semitransparent viscous liquid of yellowish color

B. Transparent liquid with cholesterol crystals

C. Blood liquid

D. Hemolyzed blood liquid

E. Turbid liquid with whitish flakes

17. After the clinical and X-ray examination of a 15-year-old patient the osteoblastoclastoma of the lower jaw was diagnosed (a cystophorous form. The diagnosis is confirmed by the specific punctuate (a brown liquid). A tumor keeps outside a cortical plate which is thin. What method of treatment should be chosen in order to apply to this tumor?

\*A. Exfoliation of the tumor simultaneously with a shell

B. Cystectomy

C. Curettage of the tumor within the limits of the healthy tissues

D. Cystotomy

E. Resection of the lower jaw with a bone plastic

18. A 12- year-old child is directed to a hospital with a suspicion of osteoblastoclastoma of the lower jaw. What of the transferred researches must be conducted for the confirmation of the clinical diagnosis?

- \*A. X-ray examination, puncture biopsy of tumor
- B. Microbiology research of puncture of the tumor
- C. Ultrasonic research of the lower jaw, cytology research of a tumor
- D. Thermovisigraphy research, Ultrasonic research of the lower jaw
- E. X-ray and ultrasonic research of the lower jaw

19. Osteoblastoclastoma (cysts form) is diagnosed in a patient of 14 years old. The resorption of the bone tissue with the area of sclerosis around it was revealed on the X-ray. Multiple shallow cavities, horizontal resorption of dental roots in the tumorous area were present. What treatment is obvious to the patient?

- \*A. Surgical
- B. Chemotherapy
- C. Symptomatic
- D. Combined
- E. Radial therapy

20. Please, find out the correct X-ray picture of odontoma:

- \*A. Dense radiopaque area with clear margins that is surrounded by halo of radiolucent area of about 1 mm
- B. Round-shaped nidus of radiopacity with clear margins
- C. Round-shaped nidus of radiopacity with unclear margins
- D. Radiolucent nidus of bone destruction with radiopaque halo
- E. Radiolucent nidus of bone destruction with unclear margins

**Recommended literature:**

1. Michael Miloro ,2004 London PETERSON'S PRINCIPLES OF ORAL AND MAXILLOFACIAL SURGERY Second Edition2
2. Pediatric Oral and Maxillofacial Surgery Leonard B. Kaban, Maria J. Troulis, 2004

**Practical class 6**

**Congenital malformations of maxillo-facial area. Cleft of lip and palate. Short frenulum of lip and tongue. Shallow vestibulum oris. Rehabilitation of children with cleft lip and palate.**

*Teaching objective:* to familiarize students with the main congenital malformation, their main classification, etiology, pathogenesis and statistics and rehabilitation.

**Pre-study test questions:**

1. Embryogenesis of the oral cavity, jaws and teeth.
2. To give the definition of “inherited disorders”, “teratogenic developmental malformation”.
3. To give the definition of “congenital malformation”, “anomaly”, “deformation”.
4. What is the difference between congenital and acquired malformation.

**Content of the class.**

There are critical points in the development of the fetus when the fusion of various prominences creates continuity and form to the lip, nose, and palate. Anomalies occur when the normal developmental process is disturbed between these components. Each of these prominences is made up of ectomesenchyme derived from neural crest tissue of the mesencephalon and rhombencephalon. Mesoderm is also present within these prominences as mesenchymal tissue. The prescribed destiny of each of these cells and tissues is controlled by various genes to alter the migration, development, and apoptosis and form the normal facial tissues of the fetus. At the molecular level there are many interdependent factors such as signal transduction, mechanical stress, and growth factor production that affect the development of these tissues.

The development of the face is coordinated by complex morphogenetic events and rapid proliferative expansion, and is thus highly susceptible to environmental and genetic factors, rationalising the high incidence of facial malformations. During the first six to eight weeks of pregnancy, the shape of the embryo's head is formed. Five primitive tissue lobes grow. If these tissues fail to meet, a gap appears where the tissues should have joined (fused). This may happen in any single joining site, or simultaneously in several or all of them. The resulting birth defect reflects the locations and severity of individual fusion failures (e.g., from a small lip or palate fissure up to a completely malformed face).

Clefts of the upper lip and palate are the most common major congenital craniofacial abnormality and are present in approximately 1 in 700 live births. Although inheritance may play a role, cleft lip and palate is not considered a single-gene disease. Instead clefts are thought to be of a multifactorial etiology with a number of potential contributing factors. These factors may include chemical exposures, radiation, maternal hypoxia, teratogenic drugs, nutritional deficiencies, physical obstruction, or genetic influences. Bilateral clefts of the lip are most often associated with clefting of both the primary and secondary palates. Cleft palate alone is seen in approximately 1 in 2,000 live births and this incidence is similar in all racial groups.

Classification of the malformations:

1. Cleft of the tissues of the oral-facial area:
  - lip;
  - coloboma;
  - macrostoma;
  - processus alveolaris;
  - palate.

2. Cleft of the tissues of the oral-facial area which are combined with other malformations ( syndromes).
3. Oro-facial dysplasia of the soft tissues and facial bones.
4. Organ deficiency or absence of its part or its tissue.
5. Developmental malformation of different organs (nose, auricle).
6. Developmental malformation of bridge of the tongue and frenulum of upper and lower lips.
7. Atresia of nasal, acoustic meatus.
8. Fistulas.

**Genetic factors** contributing to cleft lip and cleft palate formation have been identified for some syndromic cases, but knowledge about genetic factors that contribute to the more common isolated cases of cleft lip/palate is still patchy.

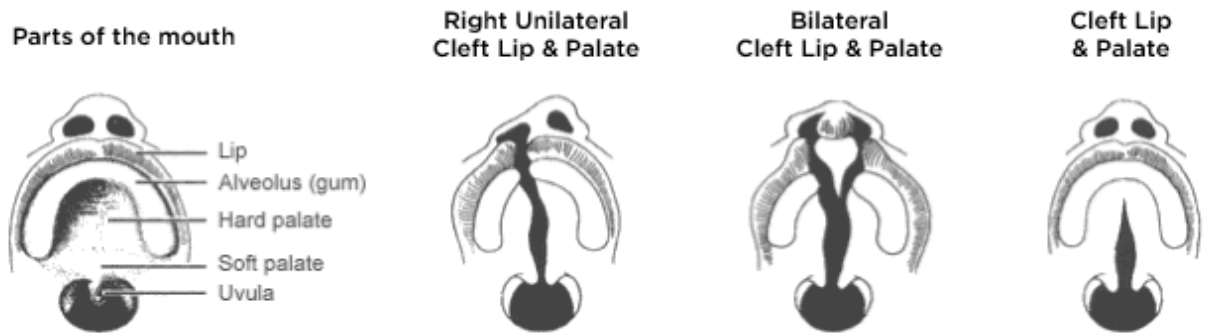
**Syndromic cases:** The Van der Woude Syndrome is caused by a specific variation in the gene *IRF6* that increases the occurrence of these deformities threefold. Another syndrome, Siderius X-linked mental retardation, is caused by mutations in the *PHF8* gene; in addition to cleft lip and/or palate, symptoms include facial dysmorphism and mild mental retardation. In some cases, cleft palate is caused by syndromes which also cause other problems. Stickler's Syndrome can cause cleft lip and palate, joint pain, and myopia. Loeys-Dietz syndrome can cause cleft palate or bifid uvula, hypertelorism, and aortic aneurysm. Cleft lip/palate may be present in many different chromosome disorders including Patau Syndrome (trisomy 13).

**Non-syndromic cases:** Many genes associated with syndromic cases of cleft lip/palate have been identified to contribute to the incidence of isolated cases of cleft lip/palate. This includes in particular sequence variants in the genes *IRF6*, *PVRL1* and *MSX1*.

Cleft palate occurs in about one in 700 live births worldwide. Palate cleft can occur as complete (soft and hard palate, possibly including a gap in the jaw) or incomplete (a 'hole' in the roof of the mouth, usually as a cleft soft palate). When cleft palate occurs, the uvula is usually split. It occurs due to the failure of fusion of the lateral palatine processes, the nasal septum, and/or the median palatine processes (formation of the secondary palate). The hole in the roof of the mouth caused by a cleft connects the mouth directly to the nasal cavity.

Bilateral clefts of the lip are most often associated with clefting of both the primary and secondary palates. Cleft palate alone is seen in approximately 1 in 2,000 live births and this incidence is similar in all racial groups.

The term **primary palate** is used to describe the anatomic structures anterior to the incisive foramen (e. g, the alveolar ridge, and maxilla). The term **secondary palate** refers to those structures posterior to the incisive foramen. Therefore, when surgeons refer to the initial or "primary" cleft palate repair, they are actually describing the closure of the secondary palate structures that include the hard palate, soft palate, and uvula. The structures of the embryologic primary palate are reconstructed later in childhood during the cleft maxillary/alveolar bone graft procedure.

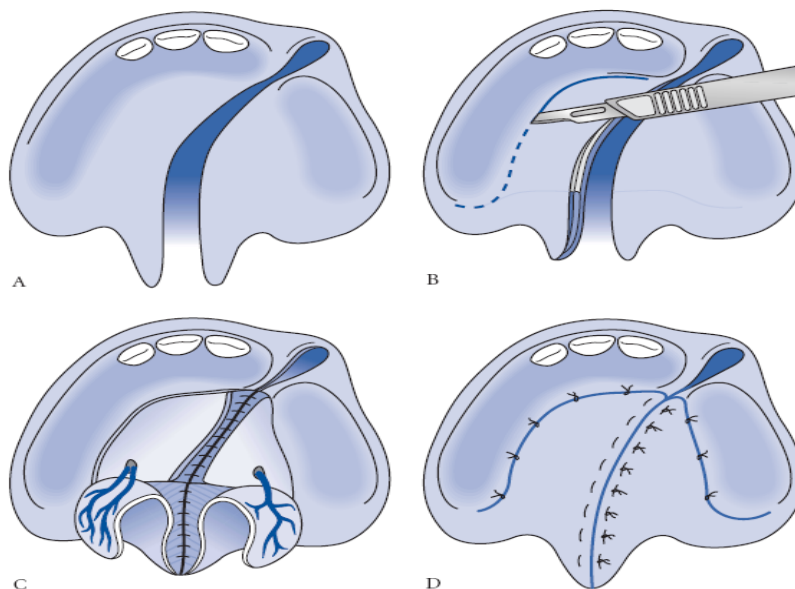


There are **two main goals** of cleft palate repair during infancy:

- 1) the water-tight closure of the entire oronasal communication involving the hard and soft palate; and
- 2) the anatomic repair of the musculature within the soft palate that is critical for normal creation of speech. The soft palate, or velum, is part of the complex coupling and decoupling of the oral and nasal cavities involved in the production of speech. When a cleft of the soft palate is present there are abnormal muscle insertions located at the posterior edge of the hard palate. Surgery must not simply be aimed at closing the palatal defect but rather at the release of abnormal muscle insertions. In patients with cleft palate, concerns for normal speech development are frequently balanced with the known biologic consequences of surgery during infancy; namely, the problem of surgery during the growth phase resulting in maxillary growth restriction.

When repair of the palate is performed between 9 and 18 months of age, the incidence of associated growth restriction affecting the maxillary development is approximately 25%. If repair is carried out earlier than 9 months of age, then severe growth restriction requiring future orthognathic surgery is seen with greater frequency.

### Scheme of palatal repair



**FIGURE 42-12** A, A unilateral cleft of the primary and secondary palates is shown with the typical involvement from the anterior vestibule to the uvula. B, The Bardach palatoplasty technique requires two large full-thickness mucoperiosteal flaps to be elevated from each palate shelf. The anterior portion (anterior to the incisive foramen) of the cleft is not reconstructed until the mixed dentition stage. C, A layered closure is performed in the Bardach palatoplasty by reapproximating the nasal mucosa. The muscle bellies of the levator palatini are elevated off of their abnormal insertions on the posterior palate. They are then reapproximated in the midline to create a dynamic functional sling for speech purposes. D, Once the nasal mucosa and musculature of the soft palate are approximated, the oral mucosa is closed in the midline. The lateral releasing incisions are quite easily closed primarily due to the length gained from the depth of the palate. In rare cases, in very wide clefts a portion of the lateral incisions may remain open and granulate by secondary intention.

### **Speech.**

Children with cleft lip generally have normal or near-normal speech. Some children with cleft palate (isolated or as part of cleft lip/palate) may develop speech a little more slowly than other children. Their words may sound nasal, and they may have difficulty producing some consonant sounds. However, after cleft-palate repair, most children eventually catch up and develop near normal speech, although some will require speech therapy or additional surgery later on.

**Orthognathic reconstruction** of maxillary and mandibular discrepancies is performed at 14 to 18 years of age based on individual growth characteristics. This is done in conjunction with orthodontics prior to and after surgery. However, in some cases of severe maxillary hypoplasia, early Le Fort I osteotomy may

be performed to optimize facial esthetics and occlusion. As with the timing of other interventions, lip and nasal revision is best reserved until after the majority of growth is complete. Most of the lip and nasal growth is complete after age 5 years. Lip revision can be considered prior to school age at about 5 years of age. However, this may be performed earlier if the deformity is severe. Nasal revision is performed after age 5 years as most of the nasal growth is also complete by this time. If orthognathic reconstruction is likely, then rhinoplasty is usually best performed after orthognathic surgery as maxillary advancement improves many characteristics of nasal support. However, when nasal deformity is particularly severe, rhinoplasty can be considered earlier even if orthognathic surgery is expected. Multiple early revisions of the lip or nose should be avoided so that excess scarring does not potentially impair ongoing growth.

### **Comprehensive control:**

1. Classification of the congenital malformation.
2. The main syndromes connected to developmental malformation of the MFA.
3. The main statistic data.
4. The most important pathogenic factors which lead to malformation development.
5. The main biological risk factors of the malformation development.
6. Preventive measures against malformation appearance.

### **Test control:**

1. What is the final period of the lower lip formation?

- \*A. The end of the first month of antenatal period
- B. The end of the second month of antenatal period
- C. The end of the third month of antenatal period
- D. The end of the fourth month of antenatal period
- E. The end of the fifth month of antenatal period

2. What is the final period of upper lip formation?

- \*A. The end of the second month of antenatal period
- B. The end of the first month of antenatal period
- C. The end of the third month of antenatal period
- D. The end of the fourth month of antenatal period
- E. The beginning of the fifth month of antenatal period

3. Latent cleft of upper lip is:

- \*A. Indrawn linear groove on the lip skin and notch on the red border of the lip



- B. Defect of the soft tissue of the upper lip which does not reach the nostrils
- C. Defect of the soft tissues of the upper lip which reaches the nostrils
- D. Defect of the soft tissues of the upper lip from both sides
- E. Defect of the bone tissue of the alveolar process in the frontal area

4. Incomplete cleft of upper lip is:

- \*A. Defect of the soft tissue of the upper lip which does not reach the nostrils
- B. Indrawn linear groove on the lip skin and notch on the red border of the lip
- C. Defect of the soft tissues of the upper lip which reaches the nostrils
- D. Defect of the soft tissues of the upper lip from both sides
- E. Defect of the bone tissue of the alveolar process in the frontal area

5. Complete cleft of upper lip is:

- \*A. Defect of the soft tissues of the upper lip which reaches the nostrils
- B. Defect of the soft tissues of the upper lip from both sides
- C. Defect of the soft tissue of the upper lip which does not reach the nostrils
- D. Indrawn linear groove on the lip skin and notch on the red border of the lip
- E. Defect of the bone tissue of the alveolar process in the frontal area

6. Parents complain of the incorrect pronunciation of certain sounds in their 7-year-old child. Objectively: the tongue is not mobile; it splits at the tip during pulling forward. The lower edge of tongue frenulum is attached in front of the excretory ducts of submandibular salivary glands. The frenulum is thin and transparent. The child is going to have the operation of frenulum elongation. What method of anaesthesia must be applied in this case?

- \*A. Infiltration anaesthesia
- B. Mandibular anaesthesia
- C. Torus anaesthesia
- D. Tuberal anaesthesia
- E. Application anaesthesia

7. Parents of a 4-year-old child complain of speech defect, improper pronunciation of the sound "R". During the examination: the tongue is restricted in its movements, with moving it forward the tongue bends down. The lower edge of tongue frenulum is attached in front of the duct of submandibular salivary glands. Frenulum is thin, transparent. Specify timing of surgical intervention.

- \*A. Once diagnosed
- B. After ending of the maxillo-facial bones growth
- C. After the eruption of permanent incisors
- D. After the formation of permanent dentition
- E. After eruption of permanent molars

8. Parents of 2-month-old boy appealed on an occasion of the birth defect of the upper lip of their child. During the examination: the tissue defect of the upper lip of the crack form on the left is defined. The crack passes through all tissues of the lips and on 4 mm is not reaching the nasal passage. The integrity of the alveolar process and hard palate is retained. Formulate a preliminary diagnosis

- \*A. Congenital latent left-sided cleft of the upper lip
- B. Congenital apparent complete left-sided cleft of the upper lip
- C. Congenital apparent incomplete left-sided cleft of the upper lip
- D. Oblique cleft of the face
- E. Congenital apparent incomplete bilateral cleft of the upper lip

9. The 3-month-child with congenital upper lip defect was hospitalized in the clinic of the maxillofacial surgery. Objectively: asymmetrical face is due to unilateral cleft of the upper lip on the left. Cleft of hard and soft palate is missing. What age is the best for the surgical treatment of this child?

- \*A. At the age of 6-8 months
- B. At the age of 1-2 months
- C. At the age of 1-2 years
- D. At the age of 2-3 years
- E. At the age of 3-4 years

10. 2 months ago the boy was diagnosed with complete isolated innate both-sided cleft lip. General somatic diseases were not found. What age is optimal to cheiloplasty of the boy?

- \*A. 3 months
- B. 12 months
- C. 9 months
- D. 18 months
- E. 6 months

11. A child of 2 years old has cleft of the soft and hard palate but without the alveolar process involvement. What form of cleft is observed?

- \*A. Isolated incomplete cleft of the palate
- B. Combined incomplete cleft of the palate
- C. Isolated complete cleft of the palate
- D. Combined complete cleft of the palate
- E. Latent form of cleft palate

12. Put the definition of the incomplete cleft palate:

- \*A. Cleft of the uvula, soft palate and sometimes hard palate, but without alveolar process involvement
- B. Cleft of the uvula, soft palate and sometimes hard palate with alveolar process involvement
- C. Cleft of the soft, hard palate with alveolar process involvement but without cleft lip
- D. Cleft of the soft, hard palate with alveolar process involvement with cleft lip
- E. Cleft of the soft, hard palate without uvula involvement

13. Put the definition of the complete cleft palate:

- \*A. Cleft of the uvula, soft palate and sometimes hard palate with alveolar process involvement
- B. Cleft of the uvula, soft palate and sometimes hard palate, but without alveolar process involvement
- C. Cleft of the soft, hard palate with alveolar process involvement but without cleft lip
- D. Cleft of the soft, hard palate with alveolar process involvement with cleft lip
- E. Cleft of the soft, hard palate with uvula involvement

14. What is the reason of the cleft palate formation?

- \*A. Failure of fusion of the lateral palatine processes, the nasal septum and/or the median palatine processes
- B. The failure of fusion of the two medial nasal processes and the frontonasal process within the embryogenesis
- C. The failure of fusion of mandibular prominences
- D. The failure of fusion frontonasal prominence with mandibular prominences

E. The failure of fusion maxillar and mandibular prominences

15. What is the reason of the cleft lip formation?

- \*A. The failure of fusion of the two medial nasal processes and the maxillary processes within the embryogenesis
- B. Failure of fusion of the lateral palatine processes, the nasal septum and/or the median palatine processes
- C. The failure of fusion of mandibular prominences
- D. The failure of fusion frontonasal prominence with mandibular prominences
- E. The failure of fusion maxillar and mandibular prominences

16. A submucous cleft of the soft palate is characterized by:

- \*A. The midline deficiency or lack of muscular tissue and incorrect positioning of the muscles
- B. Bony defect in the midline or center of the bony palate
- C. Bony defect of the alveolar process
- D. Bony defect of the hard palate and alveolar process
- E. There is no correct answers

17. A submucous cleft of the hard palate is characterized by:

- \*A. Bony defect in the midline or center of the bony palate, bifid uvula can be present
- B. Bony defect of the hard palate and alveolar process
- C. The midline deficiency or lack of muscular tissue and incorrect positioning of the muscles
- D. Bony defect of the alveolar process
- E. Bony defect of the primary palate

18. Classic clinical triad of bifid uvula, a furrow along the midline of the soft palate, a notch in a posterior margin of the hard palate are distinguished features of:

- \*A. Submucous cleft palate
- B. Incomplete cleft palate
- C. Unilateral complete cleft lip and palate
- D. Bilateral complete cleft lip and palate
- E. Latent cleft lip

19. The parents of 2-years old child complain of an abnormal nasal speech in their child, persistent middle ear diseases, feeding/swallowing difficulties. Objectively: bifid uvula and notch in the posterior margin of the hard palate are present. Clarify the diagnosis:

- \*A. Submucous cleft palate
- B. Incomplete cleft palate
- C. Complete cleft palate
- D. Unilateral complete cleft lip and palate
- E. Latent cleft lip

20. The time for surgery intervention of cleft palate is:

- \*A. 9-18 months
- B. After 10 weeks
- C. 3-4 years
- D. Immediately after setting the diagnosis
- E. 6-9 years based on dental development

**Recommended literature:**

1. Michael Miloro ,2004 London PETERSON'S PRINCIPLES OF ORAL AND MAXILLOFACIAL SURGERY Second Edition
2. Pediatric Oral and Maxillofacial Surgery Leonard B. Kaban, Maria J. Troulis, 2004

### **Practical class 7**

**Congenital malformations of maxillo-facial area. Short frenulum of lip and tongue. Shallow vestibulum oris. Rehabilitation of children with cleft lip and palate. Some concomitant nonunion of the upper lip and palate: maxillo-facial area syndromes.**

### **Practical class 8.**

**Traumatic injuries of teeth and bones of maxillo-facial area in children.**

*Teaching objective:* to familiarize students with the clinical course, diagnosis and peculiarities of treatment and rehabilitation of the patients with traumatic injuries of teeth and bone of MFA in different age.

#### **Pre-study questions:**

1. Classification of the traumas of the teeth.
2. Different types of injuries of the teeth.
3. Examination of the patient with trauma of the teeth.
4. First aid and specialized care of the children in the in-patient department and in ambulatory.
5. Complications and consequences.

#### **Content of the practical class:**

Injury to both primary and permanent teeth and the supporting structures is one of the most common dental problems occurred in children.

Researchers have shown that 30% of school children suffer traumatic dental injury in the primary dentition and 22% - in the permanent dentition. Therefore, just over 50% of children will sustain a traumatic dental injury before leaving school.

Trauma to the dentition should always be considered an emergency situation. It occurs frequently and results in functional and esthetic disturbances accompanied by concern from both the patient and the parent. The dentist's responsibility is to act objectively and efficiently in such a situation.

**Etiology.** Trauma to the dentition can be either direct or indirect. Direct trauma occurs when the dentition is struck by one of a variety of objects such as a hard ball, stick, or a fist. Indirect trauma is produced by sudden forceful closure of the mandibular teeth with their maxillary opponents as may follow a blow to the chin in a fall, a fight, or road accident.

The etiology of the various types of dental trauma is, to a large extent, dependent on age. The age and the type of trauma experienced can be divided into well-defined sections.

**Age 18 Months to 2 Years.** The age from 18 months to 2 years is an important time in the child's development. He is discovering and exploring his environment. The ability to stand unsupported has not been perfected, and locomotive movement is provided by crawling on hands and knees. Children at this age are notoriously adventurous and inquisitive, resulting in many traumatic incidents, fortunately mostly of a trivial nature. In the primary dentition, injury is usually confined to the supporting structures, resulting in displacement or avulsion of the tooth rather than fracture of the crown or root.

**Age 2 to 5: The Toddler Stage.** At the beginning of the period between the age of 2 and 5, the child is just learning to walk and is very unsteady on his feet. This may result in a fall injury to the anterior teeth. Quite often the child is taken to a park where there are swings, slides, and the like. A common cause of dental injury in this setting is the swing.

At this stage the child's oral cavity is just about on the same level as the average swing seat. Often, the child will stand in front or behind a moving swing and will receive the full force of the blow at the level of the teeth, resulting in their fracture or displacement.

**Between 5 and 10 Years.** At the stage between the ages of 5 and 10, the child has reached school age, and playground accidents are very common. These accidents tend to be falls, characterized by a high frequency of crown fracture. Also, it is the time to learn to ride a bicycle, to roller skate, and to ice skate. Falls from bicycle and skates cause multiple crown fractures with associated soft tissue injuries to the upper lip and chin.

**The Teenage Years.** Injuries during the teenage years tend to be due to sporting activities, especially contact sports such as soccer, baseball, football, basketball, and hockey.

**Road Traffic Accidents.** Facial injury owing to road traffic accidents is frequently seen in the late teens. In such an accident the passenger next to the driver is often thrown forward and may contact the windshield, causing lacerations of the soft tissues of the lip and chin.

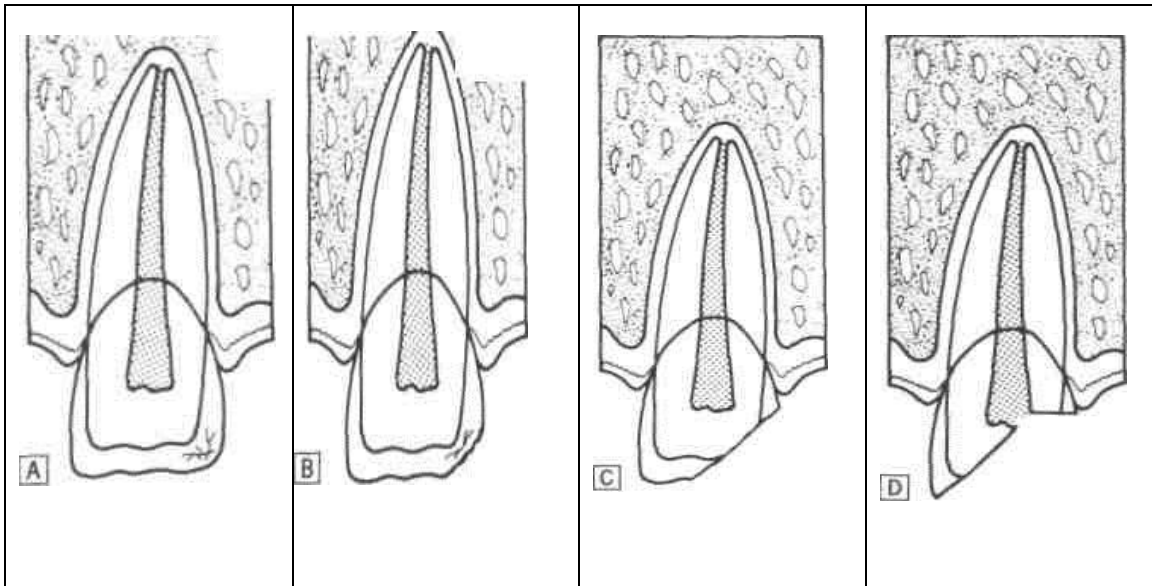
The driver and the front seat passenger are not at most risk, especially if seat belts are not worn. The trauma experienced is typified by soft tissue and bony injuries as well as damage to teeth due to contact with the windshield, dashboard, or steering wheel. Young children in rear seats are particularly at risk. If no restraint is worn, they can be thrown around the car interior in an accident, resulting in severe total body injury.

## **Injuries to the Tooth**

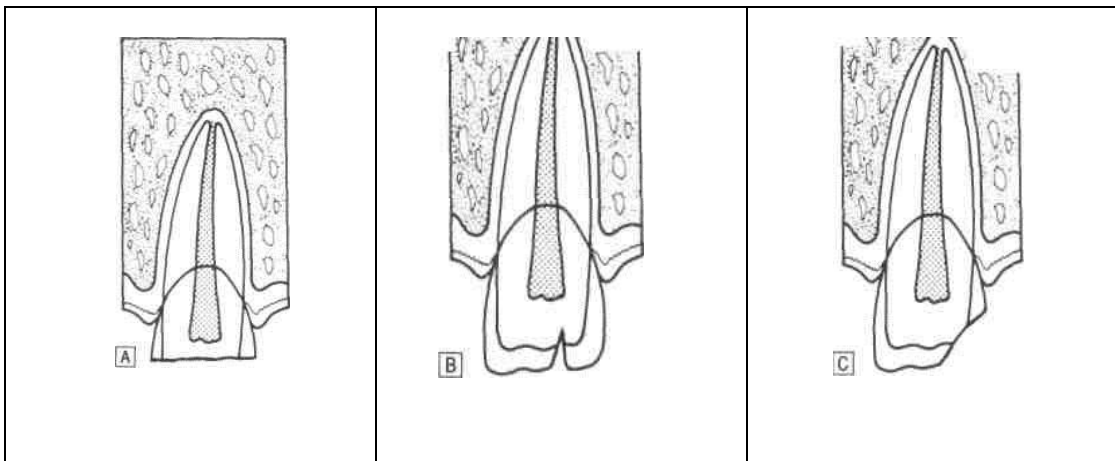
### **Crown**

A crack or craze of the enamel without loss of tooth structure can be horizontal or vertical (Fig.1-A).

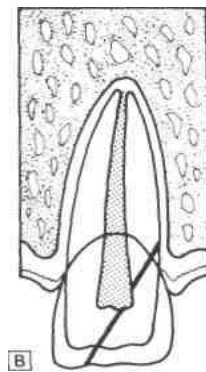
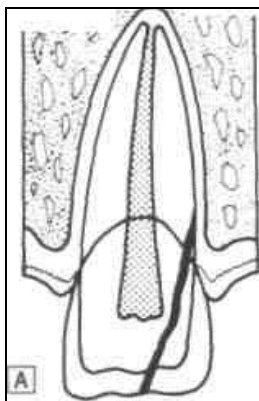
Fracture of the crown can be enamel only (Fig.1-B); involving enamel and dentine (Fig.1-C); or enamel, dentine, and pulp (Fig.1-D).



**Fig. 1** (A) Enamel crazing. (B) Crown fracture involving enamel. (C) Crown fracture involving enamel and dentine. (D) Crown fracture involving enamel, dentine and pulp. The fracture can be either horizontal (Fig.2-A); vertical (Fig.2-B); or oblique (Fig.2-C).



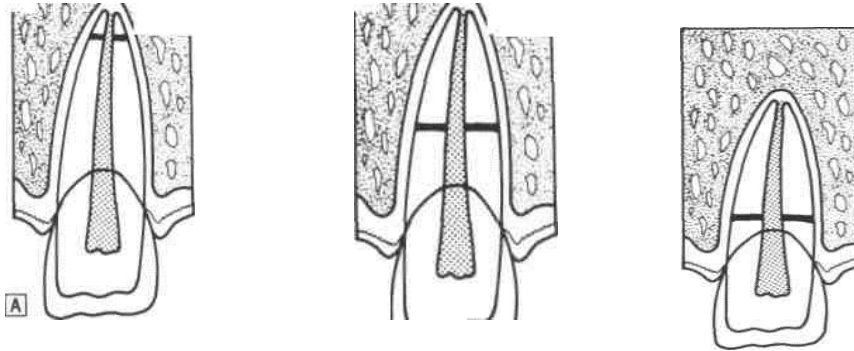
**Fig.2** A) Horizontal crown fracture (B) Vertical crown fracture. (C) Oblique crown fracture. Fracture of the crown and root involving cementum may have pulpal involvement or no pulpal involvement (Fig.3-A and B).



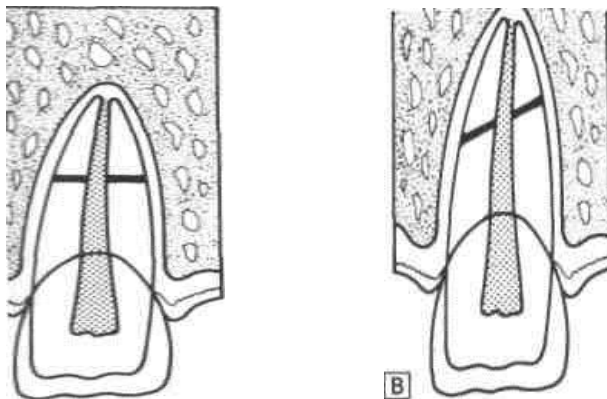
**Fig. 3** (A) Crown root fracture involving cementum. (B) Crown root fracture involving cementum and pulp.

**Root**

Fracture of the root can involve the apical third (Fig. 4-A), the middle third (Fig. 4-B), or the cervical third.



**Fig. 4** (A) Apical third root fracture. (B) Middle third root fracture. (C) Cervical third root fracture.



**Fig.5** Root fracture (A) Horizontal root fracture. (B) Oblique root fracture

**Entire tooth**

**Concussion.** A mild blow to the teeth may result in injury only to the periodontal membrane, so “concussion” of the tooth. The tooth may be sensitive to touch and tender to percussion. No mobility or displacement will be observed.

**Subluxation.** More severe blow may result in more drastic injury to the periodontal membrane resulting in tooth mobility. Any displacement is not observed.

**Displacement.** Various types of displacement can result from trauma:

- Intrusion—displacement of the tooth into the socket;
- Extrusion—partial displacement of the tooth out of its socket;
- Labial displacement—displacement of the tooth labially;
- Linguopalatal displacement—displacement toward the tongue/palate;
- Lateral displacement—displacement of the tooth mesially or distally;
- Avulsion—complete loss of the tooth from its socket

**Le Fort Classification System**

In his description of maxillary fractures Le Fort considered several factors: the vector of force overcoming the inertia of the face; the thickness of the bone and buttresses counteracting the mass, velocity, and point of application; and the maxilla, which he noticed was unaffected by muscle pull, unlike the long bones. These considerations resulted in a classification of three levels of fracture.

**Le Fort I Level.** Maxillary fractures at the Le Fort I level traverse the lateral antral wall, the lateral nasal wall, and the lower third of the septum, and they separate at the pterygoid plates. Thus, the entire mobilized segment consists of the maxillary alveolar bone, the palatine bone, the lower third of the nasal septum, and the lower third of the pterygoid plates. The superior two-thirds of these bones remain associated with the face.

**Le Fort II Level.** Maxillary fractures at the Le Fort II level involve most of the nasal bones, the maxillary bones, the palatine bones, the lower two-thirds of the nasal septum, the dentoalveolus, and the pterygoid plates. Unlike the horizontal separation noted in the Le Fort I fracture, the Le Fort II fracture is pyramidal in shape. The fracture extends from below the nasofrontal suture through the nasal bones along the maxilla to the zygomaticomaxillary suture and includes the medial inferior third of the orbit. The fracture then continues along the zygomaticomaxillary suture to and through the pterygoid plates. The septum is also separated superiorly. The segments may be intact below this line of fracture, but they are most often comminuted.

**Le Fort III Level.** Fractures at the Le Fort III level involve the nasal bones, the zygomas, the maxillae, the palatine bones, and the pterygoid plates. These fractures essentially separate the face along the base of the skull. The fracture line extends from the nasofrontal suture along the medial wall of the orbit through the superior orbital fissure. It then extends along the inferior orbital fissure and the lateral orbital wall to the zygomaticofrontal suture. The zygomaticotemporal suture is also separated. The fracture then extends along the sphenoid bone, separating the pterygoid plates. The septum becomes separated at the cribriform plate of the ethmoid. Le Fort III fractures are most often comminuted. With highly comminuted fractures, patients may sustain fractures at more than one level. Virtually all combinations of Le Fort I, II, and III fractures are possible on either side of the face.

**Comprehensive control:**

1. Classification of traumatic injuries of the jaw bones.
2. Peculiarities of the examination of children with trauma of the jaw bones.
3. Clinic and diagnostic of the fractures of upper and lower jaws in children.
4. Peculiarities of the fixation of bony fragments in children in different age.
5. Types of splints.
6. Dispenserization, rehabilitation of the patients with fractures of the jaws.

**Test control:**

1. A 6-year-old boy got a trauma of teeth. Objectively: intact crowns of the 81 and 71 teeth are shorter than neighboring. There is the mobility of the II degree, percussion reaction is mild. On the X-ray: the resorption of the 81 and 71 roots is observed on the 1/3. The roots are deep in the spongy substance. Choose the optimal method of treatment in this case:

- \*A. Extraction of teeth 71, 81
- B. Splintage of teeth 71 and 81
- C. Replacement and splintage of teeth 71 and 81
- D. Replantation of teeth 71 and 81
- E. Observation



2. A 9-year-old child was directed to the pedodontic department because of the trauma of the upper teeth. Diagnosis is the complete dislocation of the tooth 11. What treatment method should be chosen?

- \*A. Replantation of the tooth 11
- B. Orthodontic treatment of the tooth 11
- C. Prosthetic treatment of the tooth 11
- D. Implantation of the tooth 11
- E. Extraction of the tooth 11

3. During the extraction of the 46 tooth doctor did not fix the lower jaw. During the operation the patient felt the pain in the left acoustic duct area. The jaw was displaced to the left side. The attempts to close the mouth were impossible. What complication was observed?

- \*A. One-sided dislocation of the articular heads from TMJ capsule
- B. Bilateral dislocation of the articular heads from TMJ capsule
- C. Fracture of the branches of lower jaw
- D. Fracture of the articular process of the mandibula
- E. Fracture of the corner of the lower jaw

4. 5. A child of 14 years old complains of the pain of the left side area of the lower jaw which increases during mastication. Anamnesis morbi: the trauma was occurred 2 days ago. On the basis of clinic, objective and roentgenologic data the followed diagnosis has been made: opened fracture of the lower jaw between the 44 and 45 teeth. Choose the method of medical immobilization of the jaw. .

- \*A. Teeth splinting
- B. Port splint
- C. Rudko appliance
- D. Gingival plate
- E. Temporal immobilization

5. A child of 4 years old got a trauma of the face two hours ago. The diagnosis was the intrusive dislocation of the 61 tooth. What should be the doctor's manipulations?

- \*A. Observation
- B. Endodontic treatment of the 61 tooth
- C. Extraction of the 61 tooth
- D. Reposition of the 61 tooth
- E. Splintage of the 61 tooth

6. A 5-year-old child got the trauma of teeth. Objectively: the crowns of the 51 and 61 teeth are shorter than neighboring ones for 1,2 mm. The mucosa in the area of the 51 and 61 teeth is blushed and swollen. On the X-ray: the periodontal ligament in the apical area of the roots of 51 and 61 teeth is absent. The apexes of the 51 and 61 teeth are located deeply in the spongy substance of the bone. What tactic of treatment will be optimal?

- \*A. Extraction of the 51 and 61 teeth
- B. Ligature splintage
- C. Replantation
- D. Observation
- E. Reposition of the 51 and 61 teeth

7. A child is admitted to the hospital with a trauma of maxillofacial area. The possibility of tetanus infection in the wound is not excluded. What time after the injury the tetanus vaccine should be administered?

- \*A. At the time of appeal
- B. Within 12 hours
- C. During the first day
- D. Within 2 days
- E. Within a week

8. A child of 9 years old was taken to the clinic with complaints of pain in the upper jaw after fall from a height. Objectively: 12, 11, 21 teeth are mobile; teeth close at bite; hemorrhage and soreness are on the transition fold. The diagnosis is the fracture of alveolar process in the area of 12, 11, 21 teeth. Select the method of treatment.

- \*A. Splinting of a smooth tire-bracket splint
- B. Simple ligature splinting
- C. Splintage with Tigershtedt splint
- D. Sling bandage
- E. Port's splint

9. A child aged 15 months was diagnosed with intrusive luxation of the 51 tooth. What the doctor's tactic should be?

- \*A. Observation of self-eruption of the injured tooth
- B. Extraction of the 51 tooth
- C. Reposition of the 51 tooth
- D. Splintage of the 51 tooth
- E. Replantation of the 51 tooth

10. The child of 13 years old is sent to in-patient department with bilateral fracture of the mandible in the mental and angle region. On the X-ray the 34 tooth is located in the line of fracture. 4 days ago the child underwent trauma. Objectively: in the mental area the swelling of mucosa and secretion of pus in the line of the fracture are observed. What is the best doctor's tactic in this case? A. B. C. D. E.

- \*A. Extraction of the 34 tooth, jaw fragments fixation, medical supplies
- B. Reposition of the jaw fragments with preservation of the 34 tooth, medical supplies
- C. Reposition of the jaw fragments, replantation of the 34 tooth
- D. Reposition the jaw fragments, fixation of the 34 tooth by ligature splinting
- E. Medical supplies therapy, fixation of the 34 tooth by ligature splinting

11. A 14 years old child is complaining of pain in the left lower jaw, which increases during chewing, disturbances during closing of teeth. From anamnesis: the child was injured two days ago. Based on clinics, objective and radiological data the following diagnosis was clarified: open fracture of the lower jaw between 44 and 45 teeth. Choose a method of treatment for jaw immobilization.

- \*A. On-teeth splintage
- B. Temporary immobilization
- C. Porte splint
- D. Apparatus of Rudko
- E. Gum plate

12. A 10 years old boy on the fourth day after injury complains of pain in the left half of face, limited mouth opening. Objectively: significant soft tissue swelling of the left infraorbital and parotid areas. Bite is not changed. Mouth opening is limited to 1.5 cm. Attempt of movement or opening of the lower jaw is painful and "mechanical" barrier is felt. During the palpation

of the area of left zygomatic arch the invagination of the bone and mild pain are present. Clarify the preliminary diagnosis:

- \*A. Fracture of the left zygomatic arch
- B. Fracture of the left condylar process of the lower jaw bone
- C. Traumatic arthritis of the left temporo-mandibular joint
- D. Subbasal fracture of the upper jaw
- E. Medium fracture of the upper jaw

13. The 10 years old girl felt face-down over the cross-bar on the PT lesson. Objectively: symmetrical face, mouth is open, closing of it is not possible. Lower jaw moved to the left. During palpation: right articular head is not detected in the articular fossula. What is the probable diagnosis?

- \*A. Right-sided dislocation of the lower jaw
- B. Mandible fracture in the right corner area
- C. Contusion of the soft tissues in the area of the lower jaw fracture
- D. Fracture of the right coronary process
- E. Fracture of the left condyle process

14. In a child of 7 year old a full dislocation of the 11 tooth was revealed. According to anamnesis the trauma of the 11 tooth have been occurred 24 hours ago. Tooth was brought separately. Objectively: tooth socket is slightly hyperaemic, bone margins are unaffected. Socket is filled with a blood clot. Select an optimal plan of treatment.

- \*A. Replantation of tooth 11 with the previous root filling
- B. Replantation of tooth 11 with the following root filling
- C. Tooth extraction
- D. Reposition and fixation of the tooth 11
- E. Suturing of the socket

15. A 13 year old child underwent impact trauma of upper incisors. The child turned to the dentist in 40 minutes time after injury. During examination it was found that 11 and 21 teeth are intruded into the alveolar bone to the half of the crowns. Minor bleeding from the gums around the teeth was noted. Visually integrity of the mucosa is not disrupted. Pathological mobility of the 11 and 21 and adjacent teeth and alveolar bone were not found. There are no signs of teeth fractures on X-ray. What is the optimal tactic of dentist in this case?

- \*A. Extrusion of teeth 11 and 21 in the dental arch to the occlusal surface level, splintage, observation and determination if further therapiutic tratment is nessecary with EOD in a one month time
- B. Observation, EOD, antiinflammatory therapy and physiotherapy
- C. Replantation of teeth 11 and 21 after root canals filling
- D. Extrusion of teeth 11 and 21 to the tooth arch, ligation, observation, EOD
- E. teeth 11 and 21 extraction

16. A child of 6 year old is delivered to Children's Hospital by ambulance with a diagnosis: contusion-lacerated wound of the forehead. Maxillofacial surgeon was invited for consultation of the case. She examined the wound, produced an initial surgical debridement and primary sutures. Child was refered to further treatment to the regional clinic. What procedure is absolutely necessary to do in such cases?

- \*A. Consultation of neurosurgeon
- B. Hospitalization
- C. Sanation of the oral cavity
- D. Antimicrobial therapy

E. Bed regime

17. A 5-years-old child was bitten by a dog two days ago. Diagnosis - bitten cheek wound. Parents weren't refer for the help in time. Objectively: the purulent inflammatory process of the wound is present. What type of surgical debriment should be done?

- \*A. Secondary debriment
- B. Initial early debriment
- C. Initial late debriment
- D. Surgical debriment is not required
- E. Initial delayed debriment

18. A 4-years-old girl was bitten by a dog in the area of the upper lip. What solution of the listed below is primarily to process the wound?

- \*A. 10% solution of soap
- B. 0,002% chlorhexidine solution
- C. 1% solution of hydrogen peroxide
- D. 1:5000 potassium permanganate solution
- E. 3% solution of soda

19. The 3 years old child got burns from boiling water. There are different size blisters fulfilled with clear liquid on the hyperemic and swollen background of the skin. Define degree of skin burn.

- \*A. II degree
- B. I degree
- C. III degree - level A
- D. III degree - level B
- E. IV degree

20. A 13 years old patient was injured of the middle face area. The girl addressed to the doctor with complains of pain, soft tissue swelling at the side of the upper jaw, pain during closing the mouth. The examination revealed the mobility of nasal bones, significant soft tissue swelling of the left zygomatic area, hemorrhage of the sclera eyes tissue, a symptom of a "step" along the edge of both eye sockets, nosebleeds, open bite, the lengthening of the middle part of the face. Put the diagnosis:

- \*A. Fracture of the upper jaw of the Le Fort III
- B. Fracture of the upper jaw Le Fort II
- C. Fracture of the upper jaw Le Fort I
- D. Nasal bones fracture
- E. Skull base fracture

**Recommended literature:**

1. Michael Miloro ,2004 London PETERSON'S PRINCIPLES OF ORAL AND MAXILLOFACIAL SURGERY Second Edition
2. Pediatric Oral and Maxillofacial Surgery Leonard B. Kaban, Maria J. Troulis, 2004

**Practical class 9.**  
**Peculiarities of the clinical course, algorithms of diagnosis, treatment , prevention measures and the choice of the methods of the anesthesia in children with inflammation and somatic diseases of the maxillo-facial area.**

*Teaching objective:* to familiarize students with the clinical course, diagnosis and peculiarities of treatment of the patients with inflammation and somatic diseases of MFA in children.

**Pre-study questions:**

1. Etiology, clinical course of inflammatory disorders of MFA in children.
2. Types of anesthesia and its indication and contraindication in pediatric dentistry.

**Content of the practical class:**

**Indication for general anaesthesia in children:**

Emergency in children which is associated with acute odontogenic and nonodontogenic inflammatory processes in the oral cavity or maxillofacial area (periostitis, abscesses, lymphadenitis) particularly in the early age.  
Sanative intervention because of the chronic periodontitis, radicular and follicular cysts, lengthening of the short frenulum, etc.

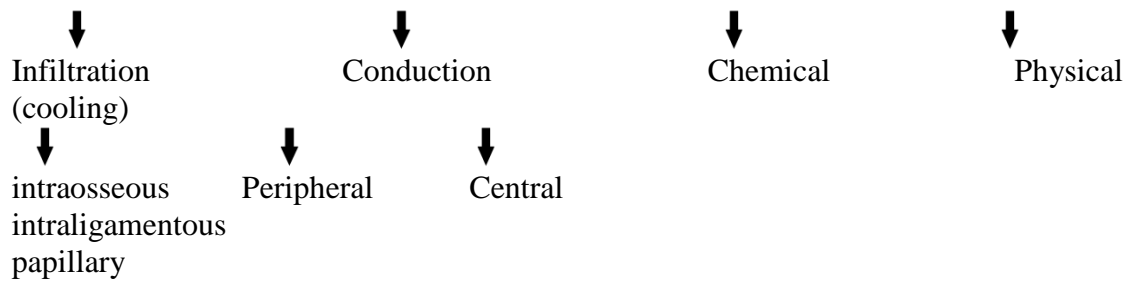
**Contraindications for general anaesthesia in children:**

- Acute or exacerbated chronic inflammatory processes of the respiratory tract;
- Acute stage of infectious diseases;
- Acute inflammatory diseases of the kidneys or urinary tracts, liver, lungs, exudative diathesis.

There are two types of local anaesthesia which are used during dental treatment:

Injectable

Noninjectable



Children may receive dental treatment in conjunction with **general anaesthesia**. An anaesthesiologist can provide general anaesthesia, while a paediatric dentist provides dental treatment. This may be done either in a hospital or dental office. General anaesthesia is defined as a controlled state of unconsciousness, accompanied by a partial or complete loss of protective reflexes, including the inability to independently maintain an open airway, and respond purposefully to physical stimulation or verbal commands.

**Local anaesthesia** is the temporary loss of sensation including pain in one part of the body produced by a topically-applied or injected agent without depressing the level of consciousness.

#### **General complications during administering of local anaesthesia:**

- loss of consciousness;
- anaphylactic reaction (collapse, anaphylactic shock);

#### **Local complications during administering of local anaesthesia:**

- entering of the infection into the tissues;
- damage of nerves and vessels, appearance of hematomas, abscesses, paresthesia damage of the adjacent organs;
- breakage of the needle;
- trismus (lockjaw) of the mandible ;
- direct injection of the solution into the blood stream;
- temporary paresis of the muscles

#### **Clinical presentation of inflammatory diseases of MFA.**

Very often, as with any infection, the patient with inflammatory processes of the maxillo- facial region will present with classic symptoms:

- Pain
- Swelling and erythema of overlying tissues in the region
- Deformation
- Adenopathy
- Fever
- Trismus
- Malaise
- The exudate may be observed during the palpation
- The causal tooth is injured (in case of odontogenic disorders)
- Mobility of the adjacent teeth (in case of odontogenic disorders)
- Paresthesia of the inferior alveolar nerve (Vensan's symptom)
- Fistulas, abscesses, phlegmon of the soft tissues.

#### **Fundamental Principles of Treatment of Infection**

In order to treat an acute dentoalveolar infection as well as a fascial space abscess correctly, the following are considered absolutely necessary:

- Take a detailed medical history from the patient.

- Drainage of pus, when its presence in tissues is established. This is achieved by way of the root canal, with an intraoral incision, with an extraoral incision, and through the alveolus of the extraction. Without evacuation of pus, that is with administration of antibiotics alone, the infection will not resolve.

- Drilling of the responsible tooth during the initial phase of inflammation, to drain exudate through the root canal, together with heat therapy. In this way, spread of inflammation is avoided and the patient is relieved of the pain. Drainage may also be performed with trephination of the buccal bone, when the root canal is inaccessible

- Antisepsis of the area with an antiseptic solution before the incision.

- Anesthesia of the area where incision and drainage of the abscess are to be performed, with the block technique together with peripheral infiltration anesthesia at some distance from the inflamed area, in order to avoid the risk of existing microbes spreading into deep tissues.

Planning of the incision so that:

- Injury of ducts (Wharton, Stensen) and large vessels and nerves is avoided

- Sufficient drainage is allowed. The incision is performed superficially, at the lowest point of the accumulation, to avoid pain and facilitate evacuation of pus under gravity .

- The incision is not performed in areas that are noticeable, for esthetic reasons; if possible, it is performed intraorally.

- Incision and drainage of the abscess should be performed at the appropriate time. This is when the pus has accumulated in the soft tissues and fluctuates during palpation, that is when pressed between the thumb and middle finger, there is a wave-like movement of the fluid inside the abscess. If the incision is premature, there is usually a small amount of bleeding, no pain relief for the patient and the edema does not subside.

- The exact localization of pus in the soft tissues (if there is no fluctuation present) and the incision for drainage must be performed after interpretation of certain data; for example, ascertaining the softest point of swelling during palpation, redness of the skin or mucosa, and the most painful point to pressure. This area indicates where the superficial incision with a scalpel is to be made. If there is no indication of accumulation of pus to begin with, hot intraoral rinses with chamomile are recommended to speed up development of the abscess and to ensure that the abscess is mature. Avoid the application of hot compresses extraorally, because this entails an increased risk of evacuation of pus towards the skin (spontaneous drainage)

- Drainage of the abscess is initially performed with a hemostat, which, inserted into the cavity of the abscess with closed beaks, is used to gently explore the cavity with open beaks and is withdrawn again with open beaks. At the same time as the blunt dissection is being performed, the soft tissues of the region are gently massaged, to facilitate evacuation of pus.

- Placement of a rubber drain inside the cavity and stabilization with a suture on one lip of the incision, aiming to keep the incision open for continuous drainage of newly accumulated pus.

- Removal of the responsible tooth as soon as possible, to ensure immediate drainage of the inflammatory material, and elimination of the site of infection. Extraction is avoided if the tooth can be preserved, or if there is an increased risk of serious complications in cases where removal of the tooth is extremely difficult.

- Administration of antibiotics, when swelling is generally diffuse and spreading, and especially if there is fever present, and infection spreads to the fascial spaces, regardless of whether there is an indication of the presence of pus. Antibiotic therapy is usually empiric,

given the fact that it takes time to obtain the results from a culture. sample. Because the microorganisms isolated most often in odontogenic infections are streptococci (aerobic and anaerobic), penicillin remains the antibiotic of choice for treatment.

Test control:

1. After the performing of torus anesthesia with the 4 ml of 2% novocaine the patient complained on hard breathing. Objectively: upper and lower lips, mucosa of the larynx and the oral cavity became swelled and blushed. What complication was observed?

- \*A. Quincker's edema
- B. Coma
- C. Collapse
- D. Anaphylactic shock
- E. Intoxication by anaesthetics

2. A 6 years old patient is referred to the dental office. The general condition of the patient: an average weight, body temperature is up to 38.5°C. Objectively: asymmetry of the face due to the slight swelling in the lower third of the right cheek and the submandibular area on the right side. The mouth opening is free. There is the deformation of the alveolar process in the area of 83, 84,85 teeth on both sides. The teeth are mobile, percussion is sharply positive.

Clarify the diagnosis:

- \*A. Acute odontogenic osteomyelitis
- B. Phlegmon of submandibular triangle
- C. Abscess of jaw-tongue groove
- D. Hematogenic osteomyelitis
- E. Acute suppurative periostitis

3. A child of 13 years old complains of changing of the colour of the upper tooth. 4 years ago there was a trauma of the frontal area on the upper jaw. Objectively: the tooth 11 is intact, percussion reaction is painless. The X-ray shows: the bone dilution near the root apex of the 11 tooth. It has the rounded form and the clear edges. What is the most reliable diagnosis?

- \*A. Odontogenic cyst of maxilla
- B. Exacerbation of granulomatous periodontitis
- C. Chronic fibrotic periodontitis
- D. Chronic granulomatous periodontitis
- E. Chronic granulating periodontitis

4. The girl of 3 years old has the following diagnosis: acute odontogenic periostitis of the lower jaw from the 74 tooth. It is necessary to conduct periostotomy and extract the 74tooth. The child is nervous. Choose the optimal type of anesthesia:

- \*A. Intravenous general anesthesia
- B. Mandibular anesthesia
- C. Intubation general anesthesia
- D. Mask general anesthesia
- E. Central anesthesia

5. A 13-year-old child had an acute odontogenic osteomyelitis of 36 tooth which was complicated by an abscess of pterygo-mandibularis area. The 36 tooth must be extracted. It is necessary to expose a pterygo-mandibularis area. What type of the anesthesia should be chosen?

- \*A. General anesthesia



- B. Tuberal and palatal anesthesia
- C. Bershe-Dubov central anesthesia
- D. Infiltration anesthesia
- E. Torus anesthesia

6. The mother of a 5-year-old child complains of the tooth decay of the upper and lower jaw. Teeth are painful during meals. Objectively: the general condition is satisfactory. A child is emotionally unbalanced. The face is symmetrical. The 54, 64, 74, 75 teeth are destroyed to the level of the gums. There are fistulas with purulent discharge from the vestibular side of the gingiva in the area of the 54, 75 teeth. What is the best method of anesthesia?

- \*A. General anesthesia
- B. Local anesthesia
- C. Application anesthesia
- D. Infiltration anesthesia
- E. Tuberal and mandibular anesthesia

7. A 5-year-old girl is ill for 3 days with fever and worsening of the general condition. Objectively: the overall condition is moderate, the body temperature is 38, 6 ° C, and the girl is pale and excited. The tongue is furred, bad breath is noted. There is the hyperemia and swelling of the mucous membrane of gums in the area of the 83, 84, 85 teeth on both sides of the alveolar ridge. These teeth are moving, percussion is sharply positive, and the 84 tooth is sealed. What is the most likely diagnosis?

- \*A. Acute odontogenic osteomyelitis of the mandible
- B. Acute odontogenic periostitis of the mandible
- C. Acute nonodontogenic periostitis of the mandible
- D. Suppurating of the odontogenic inflammatory cyst of the mandible
- E. Acute sialadenitis of the submandibular salivary gland

8. The boy is 1 month old. At the mesial margin of the right lower eyelid the wound with purulent discharge is revealed. The boy fell ill suddenly, the temperature has rose to 40 0C. General condition is severe. On the second day of the disease the infiltrate the inner edge of eye socket and cheek was occurred. The skin over it is hyperaemic, fluctuation is not defined. Eye gap is narrowed. The pus excretes from the right nasal passage. There is an infiltration on vestibular site of alveolar process and on the palate. Mucosa of transitional fold over it is hyperemic and the fluctuation is obvious. What is the most appropriate diagnosis?

- \*A. Acute hematogenous osteomyelitis
- B. Acute dacryocystitis
- C. Flegmon of orbita on the right
- D. Acute sinusitis
- E. Acute serous periostitis

9. A boy 12 years old complains of increasing temperature to 38.5 C, difficulty during opening the mouth, pain during swallowing, eating, talking. OBJECTIVE: the skin is pale; the face is slightly asymmetrical due to swelling in the left submandibular area. Opening of the mouth is limited to 12 mm, painful. Swelling of tissue in the left sublingual area, left submandibular- lingual groove is infiltrated, swollen, painful during deep palpation; mucosa in this area is hyperaemic. The crown of 36 tooth is totally destroyed. What is the diagnosis?

- \*A. Odontogenic abscesses of submandibular-lingual area caused from 36 tooth
- B. Acute odontogenic osteomyelitis of the lower jaw due to inflammatory process in the 36 tooth
- C. Acute odontogenic periostitis of the lower jaw due to inflammatory process in the 36 tooth

- D. Odontogenic phlegmon of the left pterygo-mandibular area
- E. Odontogenic phlegmon of the left submandibular area

10. Parents of the 6 years old boy complained of increased body temperature, the worsening of the general condition of their child, painful swelling of the right cheek. Objectively: paleness of the skin, facial asymmetry due to swelling of the soft tissues of the right buccal area. Alveolar bone in the area of the 55, 54 and 53 teeth is thickened on both sides, painful during palpation. Indicated teeth are partially destroyed by caries, movable (II-III degree), the pus releases from the gingival pockets. Indicate the most likely diagnosis.

- \*A. Acute odontogenic osteomyelitis of the maxilla from 53, 54, 55 teeth
- B. Acute purulent odontogenic abscess of the maxilla from 53, 54, 55 teeth
- C. Odontogenic abscess of the buccal area from 53, 54, 55 teeth
- D. Acute odontogenic serous periostitis from 53, 54, 55 teeth
- E. Odontogenic phlegmon of the buccal area from 53, 54, 55 teeth

11. The mother of 5 years old child appeals to the dentist with complaints of the child's bad feeling, fever, and pain in the lower jaw. Objectively: moderate condition, body temperature rises up to 39°C. Facial asymmetry is due to swelling of soft tissues and infiltration of the right mandible area. The 84,85 teeth are changed in color, sealed. Percussion is painful; transition fold is flattened at the area of 83,84,85,46 teeth. Mucosa is hyperemic from the vestibular and lingual side. Put the diagnosis.

- \*A. Acute odontogenic osteomyelitis of the mandible
- B. Acute suppurative periostitis of the mandible
- C. Acute serous periostitis of the mandible
- D. Exacerbation of chronic periodontitis
- E. Festering cyst of inflammatory origin

12. During providing of the local anesthesia (2 ml of 10 % lidocaine), a 9 years old girl screamed, lost consciousness, generalized convulsions began. Skin - pale, bluish. It's impossible to measure the pulse because of convulsions. Preliminary diagnosis:

- \*A. Lidocaine intoxication
- B. Angioneurotic edema
- C. Anaphylactic shock
- D. Bronchial obstruction
- E. Fever convulsions

13. After acute purulent mastitis of the mother, a swelling appeared on the left infraorbital and zygomatic areas in her 2-month-old baby. Hyperemia of the left half of the baby's face is present. The temperature rises up to 39° - 40°C. Suppuration of the nose is noted. What diagnosis can be assumed?

- \*A. Acute hematogenous osteomyelitis
- B. Phlegmon of infraorbital area
- C. Acute sinusitis
- D. Acute odontogenic osteomyelitis
- E. Acute purulent periostitis

14. A 15- year-old child complains of swelling of the mandibular process, enlargement is slightly painful. Solid lymph nodes are integrated into the "packages". There is a region of bone resorption with clear margins, containing small sequestra on radiographs of the mandible process. Mantoux test is 12 mm in diametr. What is the most probable diagnosis?

- \*A. Tuberculosis of the mandible process

- B. Actinomycosis of the mandible
- C. Chronic osteomyelitis of the mandible
- D. Acute osteomyelitis of the mandible
- E. Ewing's sarcoma

15. A 10-years-old child suffers from the edema and pain on the right cheek. The general weakness and the increase of the temperature are present. Objectively: tenderness to the palpation of the lower third of the right cheek. The skin is slightly swelled above and undertakes in a fold. The colour is without changes. Intraoral examination: the 46 tooth is blasted by caries. The cavity of the tooth is opened, probing is unpainful, percussion is slightly positive. Transitional fold in the area of the 46, 85 and 84 teeth is smoothed out, swelled. The fluctuation is absent. What is the most reliable diagnosis?

- \*A. Acute serous periostitis of the lower jaw
- B. Suppuration of the radicular cyst
- C. Acute purulent periostitis of the lower jaw
- D. Acute odontogenic osteomyelitis of the lower jaw
- E. Suppuration of the follicular cyst

16. A girl of 2 years old has the temperature 38.5 ° C, a slight swelling under the jaw from the right side is present. She was ill for 5 days, when a small mobile nodule appeared under the lower jaw on the right. Objectively: the common state of the child is satisfactory. The face is asymmetric because of a slight swelling on the right submandibular area. The skin is blushed and doesn't plicate. The poured edema on the right submandibular area is observed. It spreads to the upper part of the neck on the right side. The edema is painful, solid. The teeth are healthy. What is the most reliable diagnosis?

- \*A. Acute nonodontogenic submandibular lymphadenitis
- B. Acute sialoadenitis of the right submandibular salivary gland
- C. Adenophlegmon of the right under the mandibular area
- D. Chronic osteomyelitis of the lower jaw on the right
- E. Acute festering periostitis of the lower jaw

17. 12 hours ago a slight swelling of the left cheek appeared in a 13- year-old boy. During the examination the asymmetry of the face was observed. It was caused by the swelling of the soft tissues of the left cheek. There is tenderness to the palpation. During the intraoral examination hyperemia and edema of mucous membrane of gums on the vestibular side in the apex area of the 26 tooth was found out. The 26 tooth is blasted, percussion is sharply positive, the 26 tooth is mobile (I degree). What is the most credible diagnosis?

- \*A. Acute odontogenic periostitis
- B. Chronic odontogenic periostitis
- C. Odontogenic acute lymphadenitis
- D. Odontogenic acute osteomyelitis
- E. Odontogenic chronic osteomyelitis

18. A diagnosis has been set to the patient: odontogenic phlegmon of the right submandibular area. Define the operative access for drainage of the inflammation of the infectious etiology:

- \*A. Section in submandibular area on 2 cm below from the edge of the jaw
- B. Section in a right under lingual area
- C. Section along the edge of the jaw
- D. Section of 5 cm in length that wraps the corner of the jaw
- E. Alveolaris section

19. A diagnosis has been made to the child: abscess of a hard palate. What type of the incision is correct in this case?

- \*A. Triangular section in the area of the hard palate
- B. To conduct the puncture of an abscess
- C. The section goes parallel to the raphe of the hard palate
- D. The section in transversal direction
- E. Line section goes perpendicularly to the raphe of the hard palate

20. A girl of 12 years old complains of a slight swelling and pulsating pain in the area of the lower jaw from the right side. The temperature is 39°C. Objectively: the considerable asymmetry of the face because of the swelling in the area of the lower jaw from the right side and submandibular triangle is noted. Opening of the mouth is painful and restricted. A crown of the 46 tooth is blasted. There is a tenderness to percussion of the 46, 45, 44 teeth which are mobile. Mucosa of the lower jaw from the right side is sharply blushed, bilateral deformation of mandibular process is clearly marked, and palpation of it is painful. Lymphatic nodes are enlarged and painful during the palpation. What is the most reliable diagnosis?

- \*A. Acute odontogenic osteomyelitis of the lower jaw
- B. Osteogenic sarcoma
- C. Acute bacterial submaxillaritis
- D. Acute periostitis of the lower jaw
- E. Odontogenic submandibular phlegmon

### **Practical class 10**

**Medical history of disease. Summary module control class.**